



Retinopathy of Prematurity –Recent Screening Status in a Tertiary Care Hospital of Bangladesh

Dr. Maksudur Rahman^{1*}, Prof. Dr. Dipak Kumar Nag², Prof. Dr.Md. Mahbulul Hoque³ and Dr. Liton Chandra Saha¹

^{1*} Associate professor, Neonatology, Bangladesh institute of Childhealth (BICH), Dhaka Shishu (Children) Hospital, Dhaka, Bangladesh

² Professor and head, Department of Vitreo-Retina, National Institute of Ophthalmology & Hospital, Bangladesh

³ Professor, Neonatology, Bangladesh institute of Childhealth (BICH), Dhaka Shishu (Children) Hospital, Dhaka Bangladesh

Abstract: Retinopathy of prematurity (ROP) results in severe visual impairment and blindness in newborns. In the recent days with development of the technology to save preterm infants, it's incidence is increasing in both developed and developing countries. Only appropriate and timely screening program can prevent ROP and reduce the functional impairment of eyes. The aim of this study was to see the recent screening status of the hospital so that future plan of ROP treatment and prevention can be taken more appropriately. This prospective study was conducted from January 2018 to December 2018 in neonatology department of Dhaka Shishu (Children) Hospital. Neonates with gestational age < 34wks or birth weight, <1800gms were screened for ROP. First screening was done at 4 wks chronological age or 32 wks postmenstrual age of neonate which comes later. Then subsequent screening was done according to the findings upto 45 wks of postmenstrual age. The findings regarding incidence of ROP, types of ROP and treatment modalities of ROP along with other variables were recorded. Data were analyzed with SPSS version 17. Total 116 cases were screened for ROP. Mean gestational age was 30.7±2.4 wks and mean weight was 1420.9±313.8 gms. According to gestational age, 14 (12%) neonates with gestational age < 28 wks had ROP. Nine (7.8%) cases had ROP in both gestational age groups of 29-30wks and 31-32wks. Only 5(4.3%) cases with gestational age 33-34wks had ROP. According to birth weight, neonates with birth weight <1000 gms had ROP in 1(0.9%). Twenty four (20.7%) and 12(10.3%) cases had ROP in weight groups of 1000-1499gms and 1500-1800 gms consequently. Thirty one (26.8%) cases were found ROP in their first visit. In 6(5.1%) cases ROP were found in 2nd and subsequent visits. Among the neonates, A-P ROP was present in 15(12.9%) cases, type -I in 9 (7.7%), type- 2 in 11 (9.6%) and RD in 2(1.7%) cases. Three (2.6%) cases of type 2 ROP turned into type- 1 ROP in subsequent visits. Among the ROP cases, total 29(78%) needed treatment. Laser therapy was given in 7(24%) cases, both laser and intravitreal bivacizumab in 17 (59%) cases, only intravitreal bivacizumab in 2(7%) cases and surgery along with medical treatment was advised for 3(10%) cases. Thirty four (92%) cases had good outcome and 3 (8%) infant had no vision. The incidence of ROP was 31.9% in this study. Most of cases were A-P ROP then Z2S3 ROP. Laser plus intravitreal bivacizumab were given in most of the cases with ROP. The more number of advanced stages of ROP and a large number of babies required treatment indicates that these babies came to us in advanced stages due to irregularity and missing of follow-up.

Keywords: ROP, Retinopathy of prematurity, Screening of ROP

*Corresponding Author

Dr. Maksudur Rahman , Associate professor, Neonatology, Bangladesh institute of Childhealth (BICH), Dhaka Shishu (Children) Hospital. Dhaka, Bangladesh



Received On 23 October 2019

Revised On 21 December 2019

Accepted On 22 April 2020

Published On 01 October 2020

Funding This research did not receive any specific grant from any funding agencies in the public, commercial or not for profit sectors.

Citation Dr. Maksudur Rahman, Prof. Dr. Dipak Kumar Nag, Prof. Dr.Md. Mahbulur Rahman, Dr. Liton Chandra Saha , Retinopathy of Prematurity - Recent Screening Status in a Tertiary Care Hospital of Bangladesh.(2020).Int. J. Life Sci. Pharma Res.10(4), P31-36 <http://dx.doi.org/10.22376/ijpbs/lpr.2020.10.4.P31-36>

This article is under the CC BY- NC-ND Licence (<https://creativecommons.org/licenses/by-nc-nd/4.0>)



Copyright @ International Journal of Life Science and Pharma Research, available at www.ijlpr.com

1. INTRODUCTION

Retinopathy of prematurity (ROP) is a major cause of blindness in children.¹ It is a vascular disease of the eye unique to preterm infants characterized by failure of retinal blood vessels to grow and develop normally. It results in severe visual impairment and blindness in newborns.^{2,3} The incidence of premature births is increasing throughout the world, and with it, retinopathy of prematurity is now appearing in countries with the technology to save preterm infants. Thus, retinopathy of prematurity has become a leading cause of childhood blindness worldwide.⁴ The incidence and severity of retinopathy of prematurity are closely related to lower birth weight and earlier gestational age.⁵ The prevalence has been surveyed in most of the countries and significant variations were observed ranging from 15.6 to 36.4%.⁶⁻¹¹ Difference in prevalence among countries suggest that the race, geographic region, country, degree of social and economic development, and level of medical care are the factors influencing the incidence of retinopathy of prematurity.⁶⁻¹² Several screening program has been taken in different countries so that early diagnosis can be done and treatment can be started to prevent and decrease blindness from ROP. The criteria to screening time according to gestational age and birth weight varies in different countries.¹¹⁻¹⁶ In Bangladesh in 2013, a stakeholders' awareness and sensitisation programme was organized for neonatologists and other personnel regarding retinopathy of prematurity. Before that, screening for ROP was almost non-existent. Then different institutes began their screening program. That is very promising.¹³ there are different treatment modalities for the treatment of ROP. Cryotherapy, laser therapy and anti-vascular endothelial growth factors has been using for the management ROP.¹⁷ Earlier the cryotherapy for ROP showed the decrease of the adverse structural outcome and severe visual impairment outcome. Then laser photo coagulation demonstrated significantly better structural outcome and visual function than cryotherapy. But the outcome of surgery is not good as it was done in advanced ROP.¹⁷⁻²² This study was a part of routine newborn ROP screening activities which was started in July 2013 and was done by head of the department of vitreo-retina and his team in National Institute of Ophthalmology (NIO).

2. MATERIALS AND METHODS

This prospective observational study was conducted from January 2018 to December 2018 in neonatology department of Dhaka Shishu (Children) Hospital. The ethical clearance was taken from hospital authority and appropriate written consent was taken before each intervention from parents of neonates. Neonates with gestational age ≤ 34 wks or birth weight ≤ 1800 gms were screened for ROP. First screening was done at 4 weeks chronological age or 32 weeks postmenstrual age of neonate which comes later. Then subsequent screening was done according to the findings upto 45 wks of gestation. ROP screening was done using indirect ophthalmoscope and 20D condensing lens after dilatation of commercially available eye drop which contained 0.8% tropicamide and 5.0% phenylephrin. After dilatation screening was done by the team of ophthalmologists of NIO. After finding of ROP, it was categorized as A-P ROP, type -I, type 2 and RD (retinal detachment). Type-I, A-P (aggressive posterior) ROP and RD ROP were treated. Type -I ROP was usually treated with laser (double frequency Nd: YAG).

A-P ROP was also treated with laser. If laser could not be given appropriately then it was treated with both laser and intravitreal atavastin (0.0625 mg Bivacizumab). Besides only intravitreal atavastin was given as a rescue treatment in case of non dilated pupil and non-visualized fundus due to vitreous haziness and its most posterior position. In Stage 4b and 5 ROP, vitrectomy was advised. Both laser and intravitreal atavastin was given in NIO Operation Theater under surface anesthesia (oxy buprocaine 0.4%) in presence of anesthesiologist or neonatologist if required. Both drop dexamethasone 0.1 % and drop tobramycin 0.3% in case of laser therapy and only tobramycin 0.3% was given in case of intravitreal injection for 7 days. Follow up was done on next day and 7 days after to see any adverse effect. The outcome of treatment was considered good when retina appeared stable, no sign of active disease and child can follow the opto kinetic drum.

3. STATISTICAL ANALYSIS

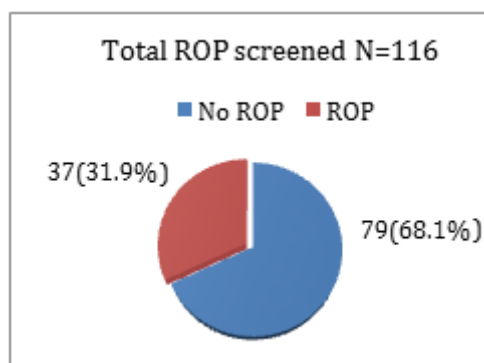
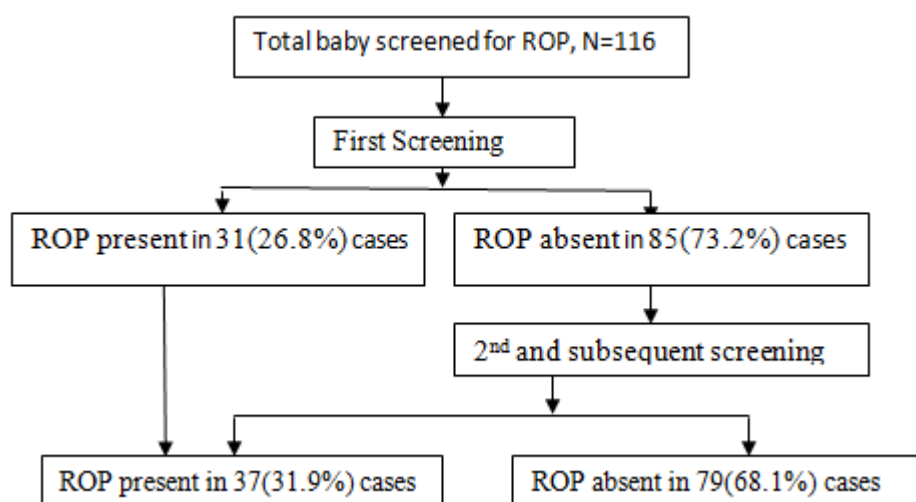
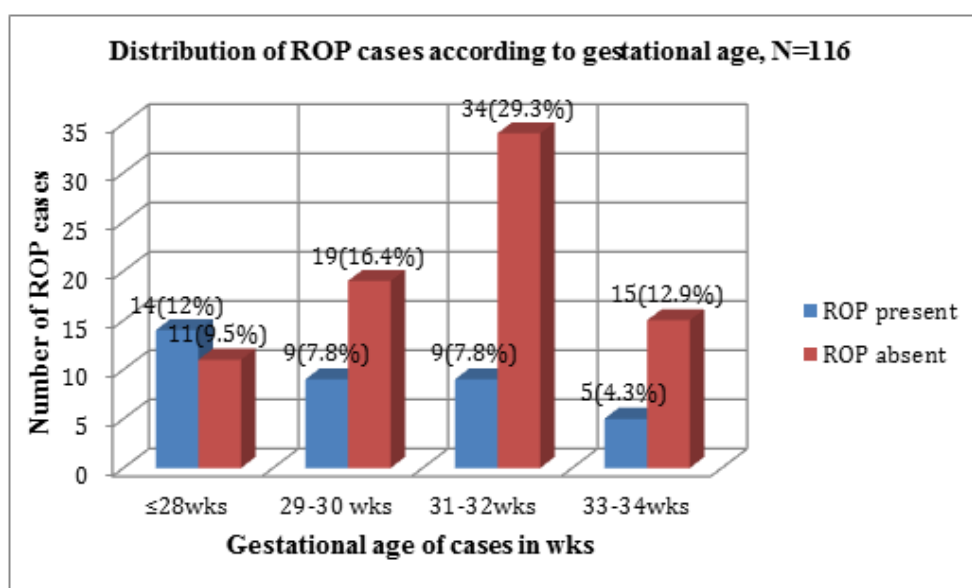
In this study main outcome variables were presence of ROP, types of ROP and treatment modalities. We collected data on gender, birth weight, gestational age, and presence of ROP, types of ROP according to ICROP classification, types of ROP according to treatment stages, treatment modalities and outcome of ROP treatment. The data were entered and analyzed using Statistical Package of Social Science SPSS, version 17. The descriptive statistics such as frequencies, percentages were calculated to summarize nominal and ordinal data, while mean and standard deviation to describe numerical variables.

4. RESULTS

During the study period from January 2018 - December 2018, total 116 cases were screened for ROP. Male were 60 (52%) and Female 56(48%). Male and female ratio was 2:1.9. Mean gestational age was 30.7 ± 2.4 wks and mean weight was 1420.9 ± 313.8 gms (Table I). Among screened cases 37(31.9%) had ROP (Figure 1). Thirty one (26.8%) neonates were found ROP in their first visit. In another 6(5.1%) cases ROP were found in 2nd and subsequent visits (Figure 2). According to gestational age, 14 (12%) neonates with gestational age ≤ 28 wks had ROP. Nine (7.8%) cases had ROP in both gestational age groups of 29-30wks and 31-32wks. Only 5(4.3%) cases with gestational age 33-34wks had ROP (Figure3). According to birth weight, neonates with birth weight <1000 gms had ROP in 1(0.9%). Twenty four (20.7%) and 12(10.3%) cases had ROP in weight groups of 1000-1499gms and 1500-1800gms consequently (Figure 4). Among the neonates , A-P ROP was present in 15(12.9%) cases, type -I in 9 (7.7%), type- 2 in ROP II (9.6%) and RD (retinal detachment) in 2(1.7%) cases. Three (2.6%) cases of type 2 ROP turned into type- I ROP in subsequent visits (Table 2). Among the neonates with ROP, 3(8.1%) cases were in zone I, 17(45.9%) in Zone 2 and no case in zone 3 (Table-3). Two (5.4%) cases had stage I, 6(16.2%) cases stage 2, 12(32.4%) cases stage 3 and 2 (5.4%) cases stage IV & V ROP (Table-3). A total 29(78%) cases needed treatment. Laser therapy was given in 7(24%) cases, both laser and intravitreal bivacizumab in 17 (59%) cases, only intravitreal bivacizumab in 2 (7%) cases and surgery along with medical treatment was advised for 3(10%) cases (Table 4). Thirty four (92%, 68 eyes) cases had good outcome and 3 (8%, 6 eyes) infant had no vision (Table 5).

Table 1. Distribution of the patients according to age, weight and sex of cases

Variables	
Mean age(wks)	30.7±2.4
Mean weight(gms)	1420.9±313.8
Sex	
Male	60(52%)
Female	56 (48%)

**Fig 1 Incidence of ROP****Fig 2. Flowchart of retinopathy of prematurity screening****Fig 3. Distribution of ROP according to gestational age**

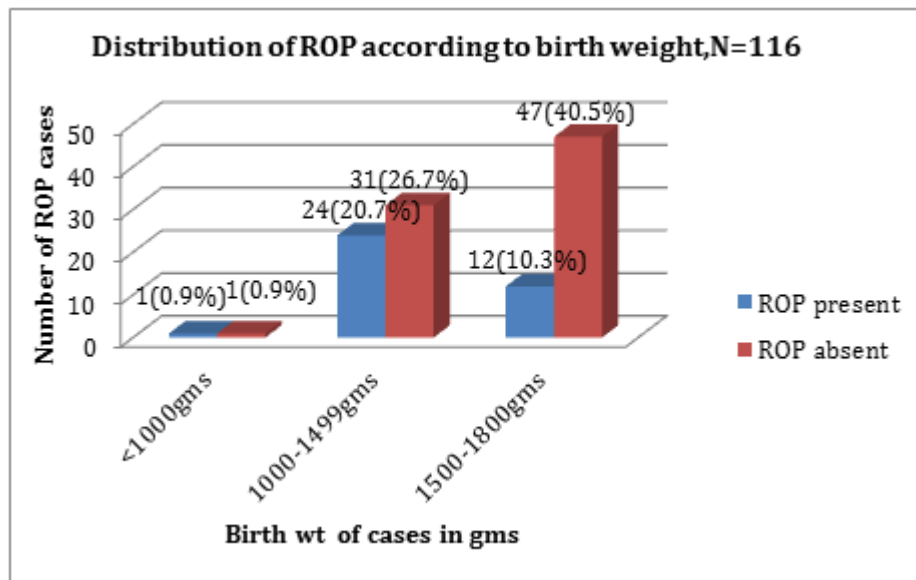


Fig 4. Distribution of ROP according to birth weight

Table 2. Distribution of types of ROP	
Type of ROP	N=116 (100%)
No ROP	79 (68.1%)
A-P ROP	15 (12.9%)
Type-1	9 (7.7%)
Type-2	11 (9.6%)
RD	2 (1.7%)

Three (3) cases of type-2 ROP turned into type-1, RD= Retinal detachment

Table 3. Distribution of stage and zone among the ROP group		
Zone	Stage	N=37 (%)
Z1	S1	0(0%)
	S2	1(2.7%)
	S3	2(5.4%)
Z2	S1	2(5.4%)
	S2	5(13.5%)
	S3	10(27%)
Z3		0(0%)
IV, V		2(5.4%)*
AP ROP		15(37.8%)*

ROP =Retinopathy of prematurity, APROP =aggressive posterior retinopathy of prematurity Plus disease (n=14)*

Table 4. Varies modalities of treatment given for ROP babies	
Treatment modalities	N=37 (%)
Laser	7 (24%)
Laser plus intravitreal bivacizumab	17 (59%)
Intravitreal bivacizumab	2 (7%)
Surgery	3(10%)

8 (22%) cases needed no treatment

Table 5. Outcome of ROP treatment	
Outcome	N=37(100%)
Good	34(92%)
No vision	3(8%)

5. DISCUSSION

This study was conducted from January 2018 to December 2018 in Neonatology department of Dhaka Shishu (Children) Hospital. During the study period, total 116 cases were

screened for ROP. Male were 60 (52%) and female 56 (48%). Male and female ratio was 2:1.9. Mean gestational age was 30.7 ± 2.4 wks and mean weight was 1420.9 ± 313.8 gms. Currently screening of ROP mainly depends on gestational age, birth weight and some unfavorable factors. The criteria

of ROP screening varies in different countries and different institutes.²³ According to guidelines of the American Academy of Pediatrics, infants with a birth weight ≤ 1500 gms or gestational age of ≤ 30 wks and selected infants with a birth weight between 1500 and 2000 gms or gestational age of more than 30 wks with an unstable clinical course, should be screened for ROP.²⁴ So the mean gestational age and mean birth weight of screened babies varies according to inclusion criteria for ROP. Sometimes these means are almost same due to same inclusion criteria. In the study of Naher et al, it was shown that mean gestational age of babies with ROP was 31.1 ± 2.3 wks and mean birth weight was 1354.2 ± 266.3 gms.¹³ The incidence of ROP is different in various study. Because there is variability in study designs, gestational ages of included infants, survival rates, and treatments used. The incidence also differs among developed and developing countries. In our study 37(31.9%) cases had ROP. In a study of Sweden ROP was present in 73% among the infant of less than 27wks and severe ROP was found 35%. In a study from Norway among the infant less than 28 wks gestational age ROP (at any stage) was reported in 33% cases.²⁵ In a prospective cohort of 552 preterm low birth weight newborns in a tertiary care hospital with or without risk factors in India, incidence of ROP was found 22.3%.²⁶ In our study the incidence of ROP was 56% (14/25) among the low gestational age ≤ 28 wks that was highest which steadily decreased with the increment of gestational ages. It was also observed that low birth weight is the other most important risk factor for the development of ROP and in this study 43.6% (24/55) babies with birth weight between 1000-1499gms had ROP. The development of ROP reduces with the increases of birth weight. Though we found only one ROP cases (among 2) with birth weight <1000 gms. The reason for this finding is that most of the babies in this group did not survive and some were lost from follow up. In our previous study as well as other studies similar results were found in preterm low birth weight babies.¹⁷ During the screening 31(26.8%) neonates were found ROP in their first visit. In 6(5.1%) cases ROP were found in 2nd and subsequent visits. It was 35% in first visit in our previous study.¹⁷ Among the neonates with ROP, A-P ROP were present in 15(12.9%) cases, type -1 in 9 (7.7%), type- 2 in 11(9.6%) and RD in 2(1.7%) cases. Three (2.6%) cases of type 2 ROP turned into type- 1 ROP in subsequent visits. Besides we found stage 1 in 2(5.4%), stage 2 in 6 (16.2%), stage 3 in 12 (32.2%) and stage IV&V in 2(5.4%) cases. Similar results were found in our previous study.¹⁷ Different studies found ROP differently. In one study Stages 1 and 2 constituted 45% of total ROP cases, stage 3 23%, stage IV 5% and stage V 9%. Aggressive posterior ROP occurred in 18% of all ROP.¹³ In a study in Brazil 6 patients (4.9%) showed retinal detachment.²⁷ In this study we got many cases with ROP in advanced stages. The reason was that these babies came lately for ROP screening. They did not follow the ROP screening follow up date properly. So we should give emphasize on counseling of parents/relatives about timely follow up of baby. In regards to treatment, both laser and intravitreal bivacizumab were given

in most of the cases with ROP (59%). Laser therapy was given in 7(24%) cases, only intravitreal bivacizumab in 2(7%) cases and surgery along with medical treatment was advised for 3(10%) cases. The outcome of surgery was not satisfactory in this study because it was done in advanced stages of ROP. Same things also observed in our previous study.¹⁷ The percent of different modalities of treatment varies in different studies. In another studies, among total 669 ROP cases, 41% babies were treated with laser, 10% with intraocular bevacizumab injection and 8% with surgery.¹³ In this study, outcome of treatment was good in 34 (92%, 68 eyes) cases and 3 (8%, 6 eyes) infant had no vision. In our previous study 5(28%, 7 eyes) cases had no vision.¹⁷ In Bangladesh, the activities of screening for ROP are more than previous activities and ROP is rapidly attaining public health significance. But it is only limited to capital city. Vast majority of neonates who stay in peripheral districts are still out of screening program and lack of timely referral is also present. There is a significant gap between the increasing need and the limited resources. The current efforts are mainly driven by the private and NGO sectors. So more government involvement and commitment is required for a nationwide sustainable program.¹³

6. CONCLUSION

The incidence of ROP was 31.9% in this study. Most of cases were A-P ROP then Z2S3 ROP. Laser plus intravitreal bivacizumab were given in most of the cases with ROP. The outcome of treatment was good. The more number of advanced stages of ROP and a large number of babies required treatment indicate that these babies came to us in advanced stages due to irregularity and missing of follow-up. So we should give proper counseling about timely follow up of infant for ROP.

7. ACKNOWLEDGEMENTS

The authors are grateful to the department of vitreo-retina, National Institute of Ophthalmology & Hospital, Bangladesh providing facilities to carry out the research work.

8. AUTHOR'S CONTRIBUTION STATEMENT

Dr. Maksudur Rahman conceptualized, gathered and analyzed the data. Prof. Dr. Dipak Kumar Nag and his team helped in screening and management of ROP infant. Prof. Dr. Md. Mahbubul Hoque supervised and contributed significantly to the writing of the manuscript. Dr. Liton Chandra Saha gave necessary inputs in designing the manuscript. All authors discussed the methodology and results and contributed to the final manuscript.

9. CONFLICT OF INTEREST

Conflict of interest declared none.

10. REFERENCES

- Chen Y, Xun D, Wang YC, et al. Incidence and risk factors of retinopathy of prematurity in two neonatal intensive care units in North and South China. *Chin Med J (Engl)*. 2015;128(7):914–8. Doi:10.4103/0366-6999.154294
- Hunter DG, Mukai S. Retinopathy of prematurity: pathogenesis, diagnosis and treatment. *Int Ophthalmol Clin* 1992;32:163–84. Doi: 10.1097/00004397-199203210-00014

3. Gibson DL, Sheps SB, Uh SH, Schechter MT, McCormick AQ. Retinopathy of prematurity induced blindness: birth weight specific survival and the new epidemic. *Pediatrics* 1990;86: 405–12.
4. Hartnett M E. Mechanisms and Management of Retinopathy of Prematurity. *N Engl J Med*. 2012 .27; 367(26): 2515–26.
Doi: 10.1056/nejmra1208129
5. Gupta N, Datti NP, Beeregowda Y, Krishnappa K, Krishnamurthy D. Study of incidence, clinical staging and risk factors of retinopathy of prematurity in rural area. *J Clin Biomed Sci*. 2013; 3: 80-4
6. Lad EM, Hernandez-Boussard T, Morton JM, Moshfeghi DM. Incidence of retinopathy of prematurity in the United States: 1997 through 2005. *Am J Ophthalmol*. 2009; 148: 451–8.
Doi: 10.1016/j.ajo.2009.04.018
7. Seiberth V, Linderkamp O. Risk factors in retinopathy of prematurity: A multivariate statistical analysis. *Ophthalmologica* 2000; 214: 131–5.
Doi: 10.1159/000027482
8. Larsson E, Carle-Petrelus B, Cernerud G, Ots L, Wallin A, Holmström G. Incidence of ROP in two consecutive Swedish population based studies. *Br J Ophthalmol*. 2002; 86: 1122–6.
Doi: 10.1136/bjo.86.10.1122
9. Shah VA, Yeo CL, Ling YL, Ho LY. Incidence, risk factors of retinopathy of prematurity among very low birth weight infants in Singapore. *Ann Acad Med Singapore*. 2005; 34: 169–78.
10. Saeidi R, Hashemzadeh A, Ahmadi S, Rahmani S. Prevalence and predisposing factors of retinopathy of prematurity in very low birth weight infants discharged from NICU. *Iran J Pediatr*. 2009; 19: 59–63.
11. Fortes Filho JB, Eckert GU, Procianoy L, Barros CK, Procianoy RS. Incidence and risk factors for retinopathy of prematurity in very low and in extremely low birth weight infants in a unit-based approach in Southern Brazil. *Eye (Lond)* 2009; 23: 25–30.
Doi: 10.1038/sj.eye.6702924
12. Shahidullah M, Dey A C, Ahmed F, Jahan I, Dey S. K, Choudhury N. and M. A. Mannan M A. Retinopathy of prematurity and its association with neonatal factors. *BSMMU J* 2017;10: 1-4.
Doi: 10.3329/bsmmuj.v10i1.30559
13. Nahar N, Badmus S A, Das S K, Malek M I A, Khan A M. Retinopathy of prematurity in Bangladesh: an overview. *community eye health. journal* 2018; 31(101) :26
14. Ahmed A S M N, Muslima H, Anwar K S, Naila Khan N Z, Chowdhury M A K A., Saha K S, and Darmstadt G L. Retinopathy of Prematurity in Bangladeshi Neonates. *Journal of Tropical Pediatrics*. 2008 ; 54(5): 333-8. Doi: 10.1093/tropej/fmn035
15. Fierston W M .Screening Examination of Premature Infants for Retinopathy of Prematurity. *Pediatrics*. 2018;142(6),1-9.e20183061.
Doi: 10.1542/peds.100.2.273
16. Abdel H. A. A. Hakeem, Gamal B. Mohamed, and Mohamed F. Othman. Retinopathy of Prematurity: A Study of Prevalence and Risk Factors. *Middle East Afr J Ophthalmol*. 2012; 19(3): 289–94.
Doi: 10.4103/0974-9233.97927
17. Saha L C, Md Mahbulul Hoque M M, Nag D K , Chowdhury MAK A. Screening for Retinopathy of Prematurity in Neonatal Unit - An Experience of a Tertiary Care Hospital in Bangladesh *Acad J Ped Neonatol* 2017;3(3) : ID.555612 .
Doi: 10.19080/ajpn.2017.02.555612
18. Hellen A, Mintz H, Ronald R. Intravitreal injection of Bivacizumab (Avastin) for treatment of stage 3 retinopathy of prematurity in zone I or posterior zone II. *Retina* .2008;;6: 831-8.
Doi: 10.1097/iae.0b013e318177f934
19. Hugo Q, Maria A, Martinez C. Antiangiogenic therapy with intravitreal bivacizumab for retinopathy of prematurity. *Retina*.2008.;3: 19-25.
Doi: 10.1097/iae.0b013e318159ec6b
20. Abdel H. A. A. Hakeem, Gamal B. Mohamed, and Mohamed F. Othman. Retinopathy of Prematurity: A Study of Prevalence and Risk Factors. *Middle East Afr J Ophthalmol*. 2012; 19(3): 289–94.
Doi: 10.4103/0974-9233.97927
21. Chen J, Stahl, A, Hellstrom A, Smith L E. Current update on retinopathy of prematurity: screening and treatment .*Curr Opin Pediatr*. 2011 ; 23(2): 173–8.
Doi: 10.1097/mop.0b013e3283423f35
22. Mannan M A, Moni S C, Shahidullah M. Retinopathy of Prematurity (ROP): Current Understanding and Management. *Bangladesh J Child Health* 2014; 38 (3) : 142-50.
Doi: 10.3329/bjch.v38i3.22823
23. Kim SJ, Port AD, Swan R, Campbell JP, Chan RVP, Chiang MF. Retinopathy of prematurity: a review of risk factors and their clinical significance. *Surv Ophthalmol*. 2018;63(5):618–37.
Doi: 10.1016/j.survophthal.2018.04.002
24. Fierston WM; Screening examination of premature infants for retinopathy of prematurity. *Pediatrics* 2013; 131: 189-195 . Doi: 10.1542/peds.2018-3810
25. Hellström A, Smith L E H, Dammann O. Retinopathy of prematurity *Lancet* 2013; 382: 1445–57.
Doi: 10.1016/s0140-6736(13)60178-6
26. Chaudhari S, Patwardhan V, Umesh Vaidya, Kadam S and Kamat A. Retinopathy of Prematurity in a Tertiary Care Center –Incidence Risk Factors and Outcome. *Indian Pediatr* 2009;46:2109-22.
27. Bassiouny R M R, Ellakkany R S, Aboelkhair S A, Mohsen T A, Ihab S. Othman I S. Incidence and risk factors of retinopathy of prematurity in neonatal intensive care units: Mansoura, Egypt *Journal of the Egyptian Ophthalmological Society* 2017; 110:71–6.
Doi: 10.4103/ejos.ejos_25_17_