



Comparative Review of Computed Tomography Scans and Radiography in Evaluating Blunt Chest Trauma

Sultan Khaled Ali Alshahrani ^{*1}, Mudhish Manea Hamad Alqorea ¹, Abdulmajeed Abdullah Alammari ², Abdullah Nasser Abdullah Al Qafrah ¹, Maryam Mansour Twiesh Alasmari ³, Hassan Mana Hassan Al Murdef ¹, Nawaf Saeed Mansour Al Sarwi ⁴, Salem Ibrahim Dhaifallah Alzahrani ⁵ and Saleem Dhafer Harmal Al Yami ⁶

^{*1} Specialist-Radiological Technology, King Khaled Hospital, Najran, Saudi Arabia.

² Specialist-Radiological Technology, King Khalid University Medical City, Abha, Saudi Arabia.

³ Specialist-Radiological Technology, Aseer Central Hospital, Abha, Saudi Arabia.

⁴ Specialist-Radiological Technology, Al Mekhwah General Hospital, Albaha, Saudi Arabia.

⁵ Specialist-Radiological Technology, King Abdulaziz Medical City, Jeddah, Saudi Arabia.

⁶ Radiology Technician, Eradah Complex for Mental Health, Najran Saudi Arabia.

Abstract: Previous comparative studies revealed that a substantial proportion of blunt chest trauma often goes unnoticed when evaluated with chest X-rays. The computed tomography scan, therefore, could play an important role in the initial assessment of patients following blunt chest trauma. This review aims to highlight the findings of chest computed tomography scans and compare them to chest radiography in patients with thoracic trauma resulting from blunt trauma. A systematic search across diverse online databases was performed in PubMed, MEDLINE, and Embase databases. The study selection process was guided by inclusion criteria that focused on individuals afflicted with chest injuries following accidents, engaged in a direct comparison of the diagnostic efficacy of chest CT scans and conventional chest X-rays, and was available in English. In the medical literature, chest radiography and CT imaging provide essential insights to guide clinical decision-making. The precise ability to distinguish between typical and atypical indications of damage across both superficial and deeper anatomical structures holds considerable importance during the initial assessment of such cases. A systematic approach, exemplified through the proposed "outside-in" sequence, offers a proficient strategy to evaluate all potential injuries comprehensively. This approach streamlines the evaluation process, ultimately empowering the medical team to promptly and effectively identify and manage these injuries.

Keywords: Trauma, Injury, Thorax, Blunt, Radiography, Tomography.

*Corresponding Author

Sultan Khaled Ali Alshahrani, Specialist-Radiological Technology, King Khaled Hospital, Najran, Saudi Arabia.

Received On 11 August, 2023

Revised On 24 August, 2023

Accepted On 29 August, 2023

Published On 1 September, 2023

Funding This research did not receive any specific grant from any funding agencies in the public, commercial or not for profit sectors.

Citation Sultan Khaled Ali Alshahrani, Mudhish Manea Hamad Alqorea, Abdulmajeed Abdullah Alammari, Abdullah Nasser Abdullah Al Qafrah, Maryam Mansour Twiesh Alasmari, Hassan Mana Hassan Al Murdef, Nawaf Saeed Mansour Al Sarwi, Salem Ibrahim Dhaifallah Alzahrani and Saleem Dhafer Harmal Al Yami, Comparative Review of Computed Tomography Scans and Radiography in Evaluating Blunt Chest Trauma.(2023).Int. J. Life Sci. Pharma Res.13(5), L418-L424 <http://dx.doi.org/10.22376/ijlpr.2023.13.5.L418-L424>

This article is under the CC BY- NC-ND Licence (<https://creativecommons.org/licenses/by-nc-nd/4.0>)

Copyright © International Journal of Life Science and Pharma Research, available at www.ijlpr.com



I. INTRODUCTION

Over half of blunt trauma incidents stem from falls or collisions involving motor vehicles. Chest injuries are the third most frequent among the various affected body regions, trailing only after head and extremity injuries.¹ These chest injuries carry a mortality rate of 10%, which is notably higher than the overall trauma mortality rate of 4.3%.² Recognizing the critical importance of chest injuries, given their association with elevated mortality rates and their contribution to heightened overall injury severity, becomes a pivotal component in the management of cases involving blunt chest trauma. In the United States, trauma causes about 100,000 deaths each year. A quarter of these fatalities from blunt trauma can be directly attributed to chest injuries.³ These injuries are often linked to motor vehicle accidents, collisions involving motorcycles, and falls.⁴ The mechanics of blunt thoracic trauma involve a significant interplay between chest wall compression and a viscous response. Rib fractures, for instance, occur when the chest wall is subjected to a force surpassing the bones' inherent elasticity. Thus, the extent of chest wall deformation corresponds to the number of fractures sustained. However, visceral thoracic trauma primarily results from the viscous response, which is a product of the instantaneous velocity of chest wall deformation and the immediate compression response of the chest wall. This dynamic elucidates how severe pulmonary and mediastinal injuries can transpire without concurrent chest wall fractures.⁵ The portable anteroposterior chest radiograph is the first modality employed to evaluate blunt thoracic trauma. These radiographs are often less than optimal within emergency settings due to challenges in positioning, subpar inspiration, or overlapping medical devices.⁶ Nonetheless, despite these limitations, it's still possible to identify numerous injuries and improperly positioned life-support devices. To increase the accuracy of thoracic injury detection, computed tomography (CT) could play a major role.⁷ The extra findings explored through CT scans have been demonstrated to influence patient management decisions. Multidetector CT (MDCT) is widely accessible, swift in execution, and permits multiplanar image reconstruction.⁸ However, magnetic resonance imaging (MRI) proves not preferable in blunt trauma due to longer acquisition times and the ferromagnetic properties of

many life-support devices.⁹ In some institutions, MRI might not even be available for emergency care. The typical imaging approach in the emergency department after an injury caused by blunt traumatic objects typically involves conducting a portable chest X-ray. This procedure primarily aims to confirm the accurate placement of medical devices and promptly identify life-threatening conditions such as tension pneumothorax.¹⁰ Based on the comparative studies analysis, a significant proportion of thoracic injuries often go unnoticed when evaluated with chest X-rays.¹¹ Approximately 20% of these injuries have the potential to impact subsequent management significantly. Hence, the CT scan could play an important role in assessing blunt chest trauma patients.¹² This article aims to review the findings of chest CT scans and compare them to conventional chest radiography in thoracic injuries resulting from blunt trauma patients.

2. MATERIALS & METHODS

A systematic search across PubMed, MEDLINE, and Embase was performed to identify the relevant scholarly works. The query utilized a combination of specific keywords, including "chest," "trauma," "CT scan," and related terms pinpointing pertinent resources, such as " (chest or thoracic or lung or rib) and (trauma or fracture or injury or blunt) and (CT scan OR computerized tomography)." Predetermined inclusion criteria guided the study selection process. These encompassed studies that focused on individuals afflicted with chest injuries following accidents, used a direct comparison of the diagnostic efficacy of chest CT scans and conventional chest X-rays and were available in English. The timeline of the study conduct was a manageable factor, as it aimed to extract comprehensive insights from historical and contemporary research. Excluded Articles by screening the title and abstract (n = 403): irrelevant articles (n = 375) and duplicated articles (n = 17). The authors did a narrative synthesis of the findings from the included studies. The discussion adopted a comparative style based on the anatomical regions involved. It started with exploring the chest wall, then focusing on the airways, chest wall, heart, and lungs. Ethical approval was not mandated because this analysis only involved a Review of previously published studies. (Figure 1 and Figure 3)

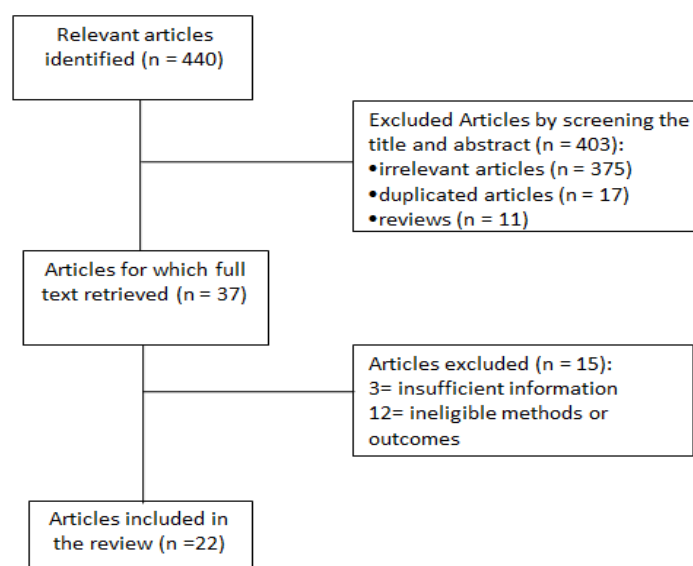


Fig 1: Flow charts of the study selection process

3. RESULTS & DISCUSSION

Following the initial search, a total of 440 studies were initially identified. Subsequent removal of duplicate entries and a preliminary assessment of titles and abstracts resulted in the retention of 37 potentially relevant studies. Upon thorough examination of the full texts, 15 studies were considered ineligible. Finally, 22 studies were deemed suitable for inclusion in the review. The findings were discussed based on the anatomical structures in the airways, chest wall, heart, and lungs.

3.1. Airways Trauma

Airway injuries aren't commonly seen in images of blunt thoracic trauma; they're usually severe and happen before people even get to the emergency room. Thus, these injuries usually occur when a motor vehicle crashes with sudden stops or when something crushes the chest. If they do happen, they could cause tears in the trachea or bronchi caused by things pushing against bones, getting pulled at attachment points, or

elevation in intrathoracic pressure against a closed glottis. Sometimes, the tears in the lateral wall of the trachea and bronchi happen where the cartilaginous rings are.^{13,14} In other cases, longitudinal tears happen in the trachea at the posterior part where it meet the cartilaginous rings. Bronchial injuries are more common than tracheal ones, and they happen more on the right side than on the left. These injuries usually occur close to the part where the trachea splits into the bronchi in the carina.¹⁵ On the radiographical examination with chest X-ray, it is difficult to detect airway injuries directly. Instead, it might appear as pneumomediastinum, leading to subcutaneous emphysema and pneumothorax with chest air, requiring thoracostomy tube insertion. Sometimes, there's bleeding into the airways, which could lead to post-obstructive pneumonia or atelectasis.¹⁶ Computed tomography is good at figuring out the site of tracheal or bronchial injury as tears in the wall directed to the cartilage rings or on the posterior membrane.¹³ Sometimes, as an indirect sign, an overall bronchial laceration could be seen in CT scans where lung called fallen lung.^{10,14}

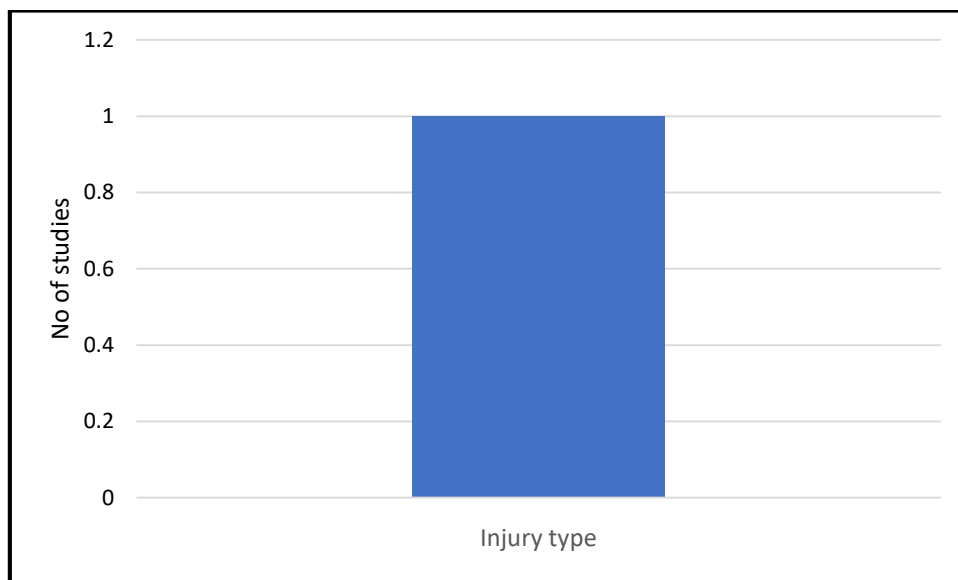


Fig 1: Chest Wall

3.2. Chest Wall

Rib fractures are the most prevalent and encompass a wide spectrum of clinical implications in chest trauma. In cases where rib fractures arise, the fragments resulting from these fractures possess the potential to convert a blunt mechanism of injury into a localized penetrating injury.¹⁷ It is important to consider the effect on surrounding soft tissues and how these fracture fragments can cause more serious injuries, such as contiguous pleura or lung lacerations. Moreover, fractures of the lower ribs might correlate with damage to abdominal organs. In contrast, although relatively uncommon, upper rib fractures could potentially relate to injuries involving neighboring vessels or the brachial plexus. On chest radiography, posterior rib fractures are typically easily identifiable, including those fractures that have shifted from their normal position. Yet, the capacity of chest radiography to detect fractures that haven't shifted is constrained. Employing targeted rib radiography can enhance the ability to detect rib fractures, although this approach has certain limitations.¹⁸ However, CT scans are the favored imaging

method for identifying rib fractures, requiring meticulous scrutiny of each rib's trajectory. Documenting multiple fractures is vital to enable swift clinical assessment of the flail chest. In addition to the customary axial evaluation, coronal reformatted images prove advantageous in elucidating uncertain findings. Rib fractures manifest in two predominant morphologies – cortex buckling and distinct fracture gaps. Significantly, careful attention should be directed toward buckle fractures, as these are prone to being overlooked.^{10,18} Fractures of the sternum usually happen when there's a direct hit or when you suddenly slow down. They're a sign that the trauma was intense and usually come with other soft tissue injuries. In case of risk of heart injury, that's a serious concern because the right ventricular wall is directly posterior to the sternum. And, when there's a sternal fracture, it can cause a serious mediastinal hematoma.¹³ On chest radiography, detecting sternal fractures on the frontal chest X-ray is rare. Lateral X-rays can detect sternal fractures better but have limited diagnostic sensitivity. On the other hand, CT scans could be useful in detecting sternal fractures when using multiplanar reconstructions to make a full sternal assessment.

Axial CT scans are not useful in detecting sternal fractures because the injury is paralleled to axial CT scans.^{10, 13} Regarding the sternoclavicular joint and clavicle, it is rarely affected by blunt thoracic trauma, but a massive blunt trauma in the chest could make sternoclavicular joints dislocate forward or backward.¹⁹ Anterior dislocation could be managed with conservative therapy using closed reduction, while posterior dislocation has a high risk for other vital chest organs such as the lungs, heart, and esophagus.²⁰ Regarding clavicle fractures, they are common in blunt thoracic trauma but, most of the time, are not a clinical concern. Clavicle fractures are usually conservatively treated, but in certain cases, an open reduction and fixation are indicated based on the angulation of the fragments.²¹ Assessing the sternoclavicular joint using conventional chest radiography is challenging, while clavicle fractures are relatively easy to observe. However, there's a bit of a hiccup here - sometimes, a distal clavicle fracture might get missed if the X-ray image is too focused.¹⁰ Angled radiography is helpful in the detection of sternoclavicular joint dislocations, but they are not commonly used in routine clinical practice. Regarding CT scans, axial CT alongside multiplanar reformations differentiate between anterior and posterior sternoclavicular joint dislocations. It is useful in detecting soft tissue injuries resulting from posterior dislocations.^{13, 22} When it is a left-sided dislocation; there is a high risk of damage to the left brachiocephalic vein due to its proximity just behind the clavicular head. Similarly, on the right side, there is the innominate artery which could be at risk due to its course. Fractures of the scapula are uncommon and usually happen when intense energy is involved. The force usually comes from the side and goes downward into the shoulder. These kinds of fractures are nearly always connected to other injuries in the thoracic area or the upper extremities. On a chest X-ray, it is easy to detect a scapular fracture and if there are any injuries to the chest or arm, but chest radiography has a limited ability to identify the characteristics and extent of scapula fractures. On the other hand, CT scans with those 3D views help understand how the fracture is angled and if the joint is affected, which is important for a treatment plan. The CT

scans with a 3-dimensional view can detect scapula fractures that go below the glenoid with force coming from the side and can show if the glenoid is affected.²³ While frequently encountered in cases involving penetrating trauma, traumatic diaphragmatic injury holds significant relevance within the realm of blunt thoracic trauma.²⁴ Overlooking such an injury might lead to the expansion of a diaphragmatic opening, potentially resulting in gradual herniation of abdominal contents through the opening. In turn, this could lead to complications such as strangulation or obstruction. In the context of blunt trauma, diaphragmatic injury is nearly always accompanied by additional injuries.²⁵ (Figure 2) Interpreting radiographic indications of blunt diaphragmatic injury requires careful consideration, and their interpretation should be aligned with CT scan findings.²⁶ Possible radiographic indicators encompass elevation of the affected hemidiaphragm, the "cottage bread" phenomenon illustrating abdominal organ herniation through the diaphragmatic breach, or even the direct protrusion of abdominal structures into the corresponding hemithorax.²⁷ The "cottage bread" sign entails abdominal contents assuming a brioche-like appearance upon herniation through the diaphragmatic opening. Another revealing finding suggestive of diaphragmatic injury involves the unusual path of a nasogastric tube above the hemidiaphragm.²⁸ Numerous CT-based indicators of diaphragmatic rupture have been documented and classified into direct signs, where a visible defect in the diaphragm is observed, and indirect signs, encompassing the consequences of diaphragmatic injury.²⁹ These signs vary in their reliability for confirming the presence of diaphragmatic injury. The most compelling evidence arises from the direct signs, where partial or complete defects in the diaphragm can be visualized. Indirect indicators of diaphragmatic injury that strongly suggest its presence include visceral herniation through the defect, the "dependent viscera" sign where the abdominal viscera closely contact the thoracic ribs and the elevation of abdominal organs above the contralateral hemidiaphragm.³⁰ Less common and less reliable markers of diaphragmatic injury are the "band" and "collar" signs, which originate from the constriction of organs herniated through a diaphragmatic defect.

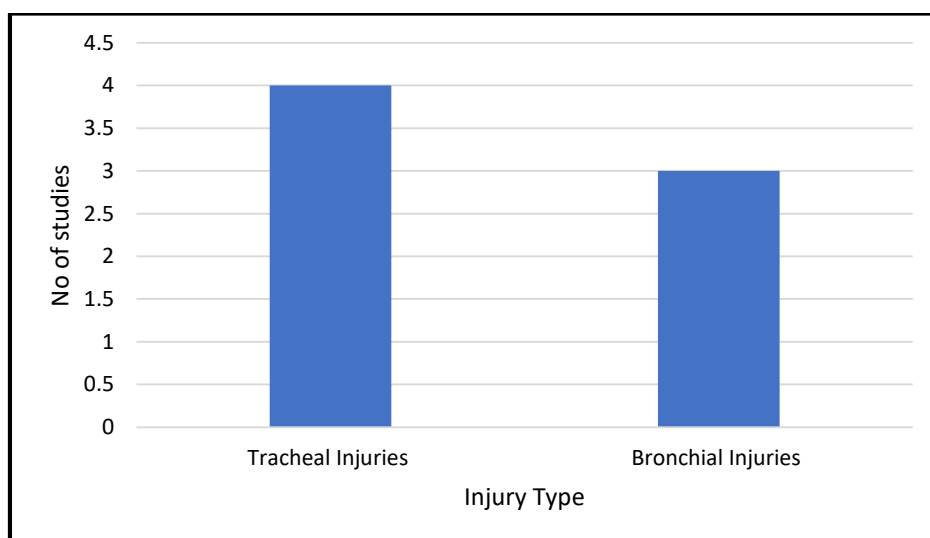


Fig 2: Airways Trauma

3.3. Heart and Lungs

Sometimes, injuries to the myocardium can rank among the most lethal traumatic injuries affecting the chest. Within blunt trauma, myocardial injury can arise from direct impact, rapid

deceleration, or, more frequently, through heart compression between the sternum and the spine. This compression of the heart is the most common mechanism.³¹ Among the cardiac chambers, the right ventricular free wall is at the highest risk of injury due to its immediate proximity to the sternum.

However, when it comes to valves, the aortic valve and mitral valve are the most susceptible to traumatic injury, largely due to heightened pressures within the left heart.³² Sometimes, cardiac malfunction can arise due to blunt trauma, even in the absence of detectable injury. The term "myocardial concussion" is employed to describe cardiac injury without anatomical or histological disruptions, while "myocardial contusion" points to physical injury or cellular disruption that elevated levels of cardiac enzyme can diagnose. The term "blunt cardiac injury" could be used to describe both of these conditions. On chest radiography, cardiac injury typically appears unremarkable, with sudden enlargement of the cardiac silhouette.³³ While most cardiac injuries accompany hemopericardium, there are cases where myocardial injury can give rise to myocardial dysfunction, culminating in subsequent cardiomegaly. Furthermore, the existence of myocardial dysfunction can trigger episodes of acute congestive heart failure, with subsequent pulmonary edema as an additional sign of cardiac injury.³⁴ The CT scans of the heart injury can detect similar observations seen on chest radiography with more precision, such as the detection of hemopericardium and pulmonary edema.¹⁴ The CT can further uncover other injuries along the course between the sternum and spine, representing the predominant mechanism of cardiac injury. The extravasation of intravenous contrast into the pericardial space or mediastinum can be detected in cases of cardiac injury with chamber perforation. An additional feature of cardiac injury on CT scans is a reduced attenuation of the affected myocardium after contrast administration.³⁵ Regarding lung trauma with blunt thoracic trauma, two distinct forms of parenchymal injury in the lungs include pulmonary

contusion and pulmonary laceration. From a pathological point of view, the key distinguishing factor between these entities lies in the absence (contusion) or presence (laceration) of alveolar disruption.³⁶ Lung contusions on radiography are seen as distinct regions of airspace opacification, as opposed to a more hazy ground-glass appearance. These markings typically become apparent around 6 hours post-injury and tend to dissipate within a span of 5 to 7 days. The temporal progression of these indications can differentiate contusion from non-traumatic pulmonary ailments such as aspiration or pneumonia. In this regard, chest radiography plays a particularly valuable role in charting the progression of these indicators, as it is frequently administered at regular intervals.³⁷ The CT scans could potentially detect lung contusions in their earlier stages. The observations show uneven airspace consolidation, which is not limited to specific segments, and the potential for subpleural regions to remain unaffected. In cases of milder contusions, the presentation could involve distinct regions of ground-glass appearance.¹⁴ In radiographic examinations, lung lacerations are most frequently observed as areas of airspace opacification when the cavity becomes filled with blood. In some instances, when a traumatic pneumatocele forms, a confined collection of air can be identified on chest radiography.³⁷ In rare cases, the laceration might resemble a pulmonary nodule. In the context of computed tomography, the differentiation of the cavity into being air-filled, blood-filled, or a combination of both is a common observation. An air-fluid level within the cavity of a traumatic hemopneumatocele is the most prevalent characteristic indicative of a pulmonary laceration.³⁸

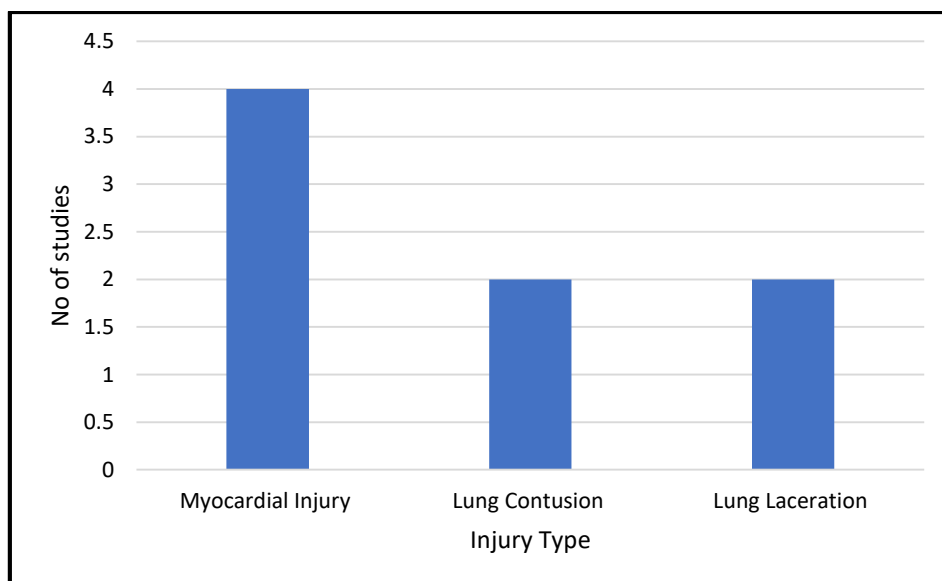


Fig 3: Heart and Lungs

4. CONCLUSION

Within the medical literature, it's widely acknowledged that thoracic injuries are frequently encountered in individuals arriving at the hospital due to blunt trauma incidents. Both chest radiography and CT imaging provide essential insights to guide clinical decision-making. The precise ability to distinguish between typical and atypical indications of damage across both superficial and deeper anatomical structures holds considerable importance during the initial assessment of such cases. A systematic approach, exemplified through the proposed "outside-in" sequence, offers a proficient strategy to

evaluate all potential injuries comprehensively. This approach streamlines the evaluation process, ultimately empowering the medical team to promptly and effectively identify and manage these injuries.

5. AUTHORS CONTRIBUTION STATEMENT

Sultan K. A. Alshahrani and Mudhish M. H. Alqorea conceived the presented idea. Sultan K. A. Alshahrani developed the conceptual framework, and Abdulmajeed A. Alammari, Abdullah N. A. Al Qafrah and Maryam M. T. Alasmari. Searched different databases. Hassan M. H. Almurdef and Saleem D. H.

Alyami did the data extraction of the included studies. All authors discussed the results and contributed to the final manuscript. Finally, Sultan K. A. Alshahrani, with Nawaf S. M. Alsarwi and Salem I. D. Alzahrani participated in the final writing of the Review.

7. REFERENCES

1. Abalkhail B, Shawky S. Prevalence of daily breakfast intake, iron deficiency anemia and awareness of anemic among Saudi school students. *International journal of food sciences and nutrition*. 2002;53(6):519-28.
2. GAILLARD M, HERVÉ C, MANDIN L, RAYNAUD P. Mortality prognostic factors in chest injury. *Journal of Trauma and Acute Care Surgery*. 1990;30(1):93-6.
3. Calhoun JH, Trinkle JK. Pathophysiology of chest trauma. *Chest surgery clinics of North America*. 1997;7(2):199-211.
4. Karmy-Jones R, Jurkovich GJ, Nathens AB, Shatz DV, Brundage S, Wall MJ, et al. Timing of urgent thoracotomy for hemorrhage after trauma: a multicenter study. *Archives of Surgery*. 2001;136(5):513-8.
5. Viano DC, Lau IV, Asbury C, King AI, Begeman P. Biomechanics of the human chest, abdomen, and pelvis in lateral impact. *Accident Analysis & Prevention*. 1989;21(6):553-74.
6. Kuhlman JE, Pozniak MA, Collins J, Knisely BL. Radiographic and CT findings of blunt chest trauma: aortic injuries and looking beyond them. *Radiographics*. 1998;18(5):1085-106.
7. Weninger P, Mauritz W, Fridrich P, Spitaler R, Figl M, Kern B, et al. Emergency room management of patients with blunt major trauma: evaluation of the multislice computed tomography protocol exemplified by an urban trauma center. *Journal of Trauma and Acute Care Surgery*. 2007;62(3):584-91.
8. Stillman AE, Oudkerk M, Ackerman M, Becker CR, Buszman PE, De Feyter PJ, et al. Use of multidetector computed tomography for the assessment of acute chest pain: a consensus statement of the North American Society of Cardiac Imaging and the European Society of Cardiac Radiology. *The International Journal of Cardiovascular Imaging*. 2007;23:415-27.
9. Mirvis SE, Shanmuganathan K. MR imaging of thoracic trauma. *Magnetic Resonance Imaging Clinics of North America*. 2000;8(1):91-104.
10. Ho M-L, Gutierrez FR. Chest radiography in thoracic polytrauma. *American Journal of Roentgenology*. 2009;192(3):599-612.
11. Ziegler K, Feeney JM, Desai C, Sharpio D, Marshall WT, Twohig M. Retrospective Review of the use and costs of routine chest x rays in a trauma setting. *Journal of Trauma Management & Outcomes*. 2013;7(1):1-6.
12. Omert L, Yeane WW, Protetch J. Efficacy of thoracic computerized tomography in blunt chest trauma. *The American surgeon*. 2001;67(7):660-4.
13. Kaewlai R, Avery LL, Asrani AV, Novelline RA. Multidetector CT of blunt thoracic trauma. *Radiographics*. 2008;28(6):1555-70.
14. Oikonomou A, Prassopoulos P. CT imaging of blunt chest trauma. *Insights into imaging*. 2011;2(3):281-95.
15. Kiser AC, O'Brien SM, Detterbeck FC. Blunt tracheobronchial injuries: treatment and outcomes. *The Annals of Thoracic Surgery*. 2001;71(6):2059-65.
16. Sangster GP, González-Beicos A, Carbo AI, Heldmann MG, Ibrahim H, Carrascosa P, et al. Blunt traumatic injuries of the lung parenchyma, pleura, thoracic wall, and intrathoracic airways: multidetector computer tomography imaging findings. *Emergency radiology*. 2007;14:297-310.
17. Simon B, Ebert J, Bokhari F, Capella J, Emhoff T, Hayward III T, et al. Management of pulmonary contusion and flail chest: an Eastern Association for the Surgery of Trauma practice management guideline. *Journal of Trauma and Acute Care Surgery*. 2012;73(5):S351-S61.
18. Malghem J, Vande Berg BC, Lecouvet FE, Maldague BE. Costal cartilage fractures as revealed on CT and sonography. *American Journal of Roentgenology*. 2001;176(2):429-32.
19. Van Tongel A, De Wilde L. Sternoclavicular joint injuries: a literature Review. *Muscles, Ligaments and Tendons Journal*. 2011;1(3):100.
20. Hoekzema N, Torchia M, Adkins M, Cassivi SD. Posterior sternoclavicular joint dislocation. *Canadian Journal of Surgery*. 2008;51(1):E19.
21. Bajuri MY, Maidin S, Rauf A, Baharuddin M, Harjeet S. Functional outcomes of conservatively treated clavicle fractures. *Clinics*. 2011;66:635-9.
22. Buckley BJ, Hayden SR. Posterior sternoclavicular dislocation. *Journal of Emergency Medicine*. 2008;34(3):331-2.
23. Cole PA, Gauger EM, Schroder LK. Management of scapular fractures. *JAAOS-Journal of the American Academy of Orthopaedic Surgeons*. 2012;20(3):130-41.
24. Shibahashi K, Kato T, Hikone M, Sugiyama K. The epidemiological state of blunt diaphragmatic injury: An analysis of a nationwide trauma registry in Japan. *Injury*. 2023.
25. Perlman S, Rogers LF, Mintzer RA, Mueller C. Abnormal course of nasogastric tube in traumatic rupture of left hemidiaphragm. *American journal of roentgenology*. 1984;142(1):85-8.
26. Mude NN, Prakash S, Shaikh O, Vijayakumar C, Kumbhar U. Traumatic Diaphragmatic Rupture With Pericardial Tear and Transdiaphragmatic Herniation of the Stomach. *Cureus*. 2022;14(9).
27. Sridhar S, Raptis C, Bhalla S, editors. *Imaging of blunt thoracic trauma*. *Seminars in roentgenology*; 2016: Elsevier.
28. Paes FM, Durso AM, Danton G, Castellon I, Munera F. Imaging evaluation of diaphragmatic injuries: improving interpretation accuracy. *European journal of radiology*. 2020;130:109134.
29. Safari S, Farbod M, Hatamabadi H, Youseffard M, Mokhtari N. Clinical predictors of abnormal chest CT scan findings following blunt chest trauma: A cross-sectional study. *Chinese Journal of Traumatology*. 2020;23(1):51-5.
30. Ramachandran P. *A Study of Computed Tomography Evaluation of Blunt Abdominal Injury: Coimbatore Medical College, Coimbatore; 2019.*

6. CONFLICT OF INTEREST

Conflict of interest declared none.

31. Orliaguet G, Ferjani M, Riou B. The heart in blunt trauma. *The Journal of the American Society of Anesthesiologists*. 2001;95(2):544-8.
32. Kan C-D, Yang Y-J. Traumatic aortic and mitral valve injury following blunt chest injury with a variable clinical course. *Heart*. 2005;91(5):568-70.
33. Restrepo CS, Gutierrez FR, Marmol-Velez JA, Ocazonez D, Martinez-Jimenez S. Imaging patients with cardiac trauma. *Radiographics*. 2012;32(3):633-49.
34. Offenbacher J, Liu R, Venitelli Z, Martin D, Fogel K, Nguyen V, et al. Hemopericardium and Cardiac Tamponade After Blunt Thoracic Trauma: A Case Series and the Essential Role of Cardiac Ultrasound. *J Emerg Med*. 2021;61(3):e40-e5.
35. Katabathina VS, Restrepo CS, Martinez-Jimenez S, Riascos RF. Nonvascular, nontraumatic mediastinal emergencies in adults: a comprehensive review of imaging findings. *Radiographics*. 2011;31(4):1141-60.
36. Miller DL, Mansour KA. Blunt traumatic lung injuries. *Thoracic Surgery Clinics*. 2007;17(1):57-61.
37. Polireddy K, Hoff C, King NP, Tran A, Maddu K. Blunt thoracic trauma: role of chest radiography and comparison with CT—findings and literature Review. *Emergency Radiology*. 2022;29(4):743-55.
38. Stulz P, Schmitt H, Hasse J, Grädel E. Traumatic pulmonary pseudocysts and paramediastinal air cyst: two rare complications of blunt chest trauma. *Journal of Trauma and Acute Care Surgery*. 1984;24(9):850-3.