



## A Case Study On Successful Management of Complicated Fistula in Ano with CKD and Septic Shock Through Integrated Surgical Approach

Dr. Shreya Soni<sup>1\*</sup>  Dr. Sheetal Asutkar<sup>2</sup>, Dr. Sandeep Kumar Upadhyay<sup>3</sup> and Dr. Yogesh Yadav<sup>4</sup>

<sup>1\*</sup> PG Scholar, Department of Shalya Tantra, Mahatma Gandhi Ayurved College Hospital and Research Centre, Salod (Hi), Datta Meghe Institute of Higher Education and Research, Wardha 442001.

<sup>2</sup> MS (Ayu), Ph.D., Professor & HOD Shalya Tantra, Mahatma Gandhi Ayurved College Hospital and Research Centre, Salod (Hi), Datta Meghe Institute of Higher Education and Research, Wardha 442001.

<sup>3,4</sup> PG Scholar, Department of Shalya Tantra, Mahatma Gandhi Ayurved College Hospital and Research Centre, Salod (Hi), Datta Meghe Institute of Higher Education and Research, Wardha 442001.

**Abstract:** Swelling, discomfort, redness, soreness, and a localized increase in temperature are the clinical signs of an abscess. Fistula in ano, the complication most frequently with perianal abscess, is caused by poor pus drainage or incorrect dressing in the post-operative stage. Modern science describes treatment as a two-step process, including an incision and drainage. An abscess can be correlated to *Vidradhi* in *Ayurveda*. The irritated *Dosha* affects the *tweek, rakta, means, media, and asthi; majja* becomes localized and causes a problematic swelling known as *Vidradhi* that is deeply ingrained, painful, and expands steadily. When its *Pakwa avastha* is complete, the *vidradhi* opens up or bursts. At this stage, we must perform *bhedhana karma* to drain the vitiated materials that cause a cavity. The case presented was a recurrent Perianal abscess associated with fistula in ano with Chronic Kidney Disease (CKD) in which the patient had severely deranged Kidney functions, poor signs of oral nutrition, swollen feet and ankles, puffiness around eyes, oliguria leading to Septic Shock, was managed through Surgical and integrated approach of *Ayurveda*. The method followed here is pre-operative medications which was the utmost emergency as the patient was in Septic shock, and then the surgical management, i.e., Incision (*Bhedana*) leading to immediate drainage of peri-anal abscess followed by *Ksheerasutra* application for complete drainage along with cutting & healing of the cavity. The planned treatment of the *Ksheerasutra* application after I & D resulted in a complete cure for the condition. This case study provides the successful emergency management of *Gudagata vidradhi* with *Bhagandara* and comorbidities via surgical & Ayurvedic management.

**Keywords:** *Sushruta, Ayurveda, Kshara sutra, Guda vidradhi, Incision*

### \*Corresponding Author

Dr. Shreya Soni, PG Scholar, Department of Shalya Tantra, Mahatma Gandhi Ayurved College Hospital and Research Centre, Salod (Hi), Datta Meghe Institute of Higher Education and Research, Wardha 442001.



Received On 25 October, 2022

Revised On 2 May, 2023

Accepted On 31 May, 2023

Published On 1 November, 2023

**Funding** This research did not receive any specific grant from any funding agencies in the public, commercial or not for profit sectors.

**Citation** Dr. Shreya Soni, Dr. Sheetal Asutkar, Dr. Sandeep Kumar Upadhyay and Dr. Yogesh Yadav, A Case Study On Successful Management of Complicated Fistula in Ano with CKD and Septic Shock Through Integrated Surgical Approach.(2023).Int. J. Life Sci. Pharma Res.13(6), P28-P36 <http://dx.doi.org/10.22376/ijlpr.2023.13.6.P28-P36>

This article is under the CC BY- NC-ND Licence (<https://creativecommons.org/licenses/by-nc-nd/4.0>)

Copyright © International Journal of Life Science and Pharma Research, available at [www.ijlpr.com](http://www.ijlpr.com)

Int J Life Sci Pharma Res., Volume13., No 6 (November) 2023, pp P28-P36



## 1. INTRODUCTION

Humans frequently suffer from anorectal disorders such as abscesses, fistulas, and piles. Fistula and abscess are the acute and chronic stages of the same anorectal infection. An infection in the anal glands that spreads into nearby regions and creates a fistula is the first sign of an abscess.<sup>1</sup> There are 8.6 incidences of anal fistula for every 100,000 people. Anorectal abscess, which develops due to an infection of the glandular epithelium of the anal canal, causes 40 percent of fistulas.<sup>2</sup> The most distinguishing sign of an ano rectal abscess, also known as a *Gudavidradhi* in *Ayurveda*, is excruciating pain in the anal area and, if a fistula forms, pus drainage. Therefore, anorectal abscesses are treated with early, sufficient, and dependent drainage. Despite being surgical in all cases, treating a fistula is more difficult since a fistulotomy may cause fecal incontinence and can occasionally result in complications and recurrence. Incision (*Bhedana*) is counseled by *Sushruta* (the legendary Indian surgeon) because the primary treatment of *Vidradhi* (abscess)<sup>3</sup> and once it turns to fistula, the management by *ksharasutra* is found effective in terms of early healing of the wound. *Ksharasutra*, a W.H.O. recognized para-surgical procedure, is widely used in such cases throughout India. In the case of *Bhagandara* (Fistula-in-ano), also *Sushruta* mentioned the application of *Kshara* (alkaline ash)<sup>4</sup>. Later, *Chakrapani* and *Bhavamishra* detailed the preparation and application of *Ksharasutra* in *Bhagandara* (Fistula in-ano)<sup>5</sup>. A case of recurrent perianal abscess with complicated horseshoe fistula in ano is successfully treated by Incision, and *shastra* application is presented here. The aim of this case study is the successful management of complicated fistula in ano with comorbidity. To assess the application of *Udumber ksheerasutra* and *Panchavalakal* ointment after Surgical intervention of perianal abscess with a fistular track. The current case will be an outstanding example of treating a compromised Renal condition through emergency management and then dealing with abscess management. Also, there is a lot of work in *ksharasutra chikitsa* for *Bhagandara*. Still, this case proves an immense drainage, cutting, and healing effect of *Ksheerasutra* in its present condition, which has yet to be widely known.

## 2. CASE REPORT

A Male patient, 48 years of age, an Employee of Pharmacy College, came with recurrent Perianal Abscess with Fistula in ano and co-morbidities and was treated successively with a holistic approach and a successful surgical and Integrated medical approach.

### 2.1. Medical History

#### Current

Huge Boil in the left perianal region for two weeks. Pain and profuse pus discharge from the boil for the past 12 days. Intermittent fever and loss of appetite for the past week. Generalized weakness for the past week. The patient was well before two weeks but gradually developed a boil in the Left perianal region and had severe Pain and discomfort along with blood and pus discharge from it. He also had complaints of generalized weakness and was dehydrated. He had a history of recurrent perianal abscess and fistula in ano twice in the past two years and was already managed with Incision and drainage. So for further management, he came to Shalya OPD, MGACH& RC and was admitted to the Male surgical ward.

### 2.2. Previous History

### 2.3. Medical history

He was labeled with Chronic renal disease for the past two years and was under medication. K/C/O- Hypertension for the 2 years, under medication. No H/O DM/PTB/Thyroid disorder. Surgical history: Fistula in Ano, Recurrent & Horseshoe shaped since 12/6/2020 (MRI Fistulogram). Incision and drainage was done for the first time in June 2020. Probing and KS application on 30 June 2020. Incision and drainage was done for the second time in August 2020. Drug History: Tab Cilacar 5mg I OD - Before food, Tab Calcibiz MZ- IHS, Tab Acizo IgM BD - After food since 2 years, Tab Chlorthiazide 12.5mg I OD - After food, Tab Nephrosave 150mg IBD, Tab Clonazepam I HS after food since Nov2021. For the past 15 days: Tab Metrogl ER 600mg I BD after food, Tab Cavum 625mg ITDS after food, Tab Supenta DSR-I OD

### 2.4. Family history

Nothing specific

### 2.5. Personal history

No Addiction to Alcohol or tobacco. Diet- Vegetarian, Sleep-Disturbed

### 2.6. 8 Fold examination (Ashtavidha Pariksha)

Nadi- 80/min, Mala- Once a day, Normal consistency, Mutra-Concentrated, quantity reduced, Jivha- Coated, Dry, Shabda-Normal, Sparsha- Ushna, (Febrile), Drika- Pallor, Akriti-Madhyam

### 2.7. General examination on admission

BP- 80/60 mm of Hg, Pulse- 80/min, feeble, Temperature- 99.6 F, Respiration- 16/min, Pallor present, Icterus absent, Lymphadenopathy absent, Oedema - Mild and Generalised, Cyanosis absent.

### 2.8. Vrana Parikshal/ Local Examination

### 2.9. On Inspection

Burst boil at the left perianal region at 2 to 5'0 clock position with blood mixed and purulent discharge.

### 2.10. On Palpation

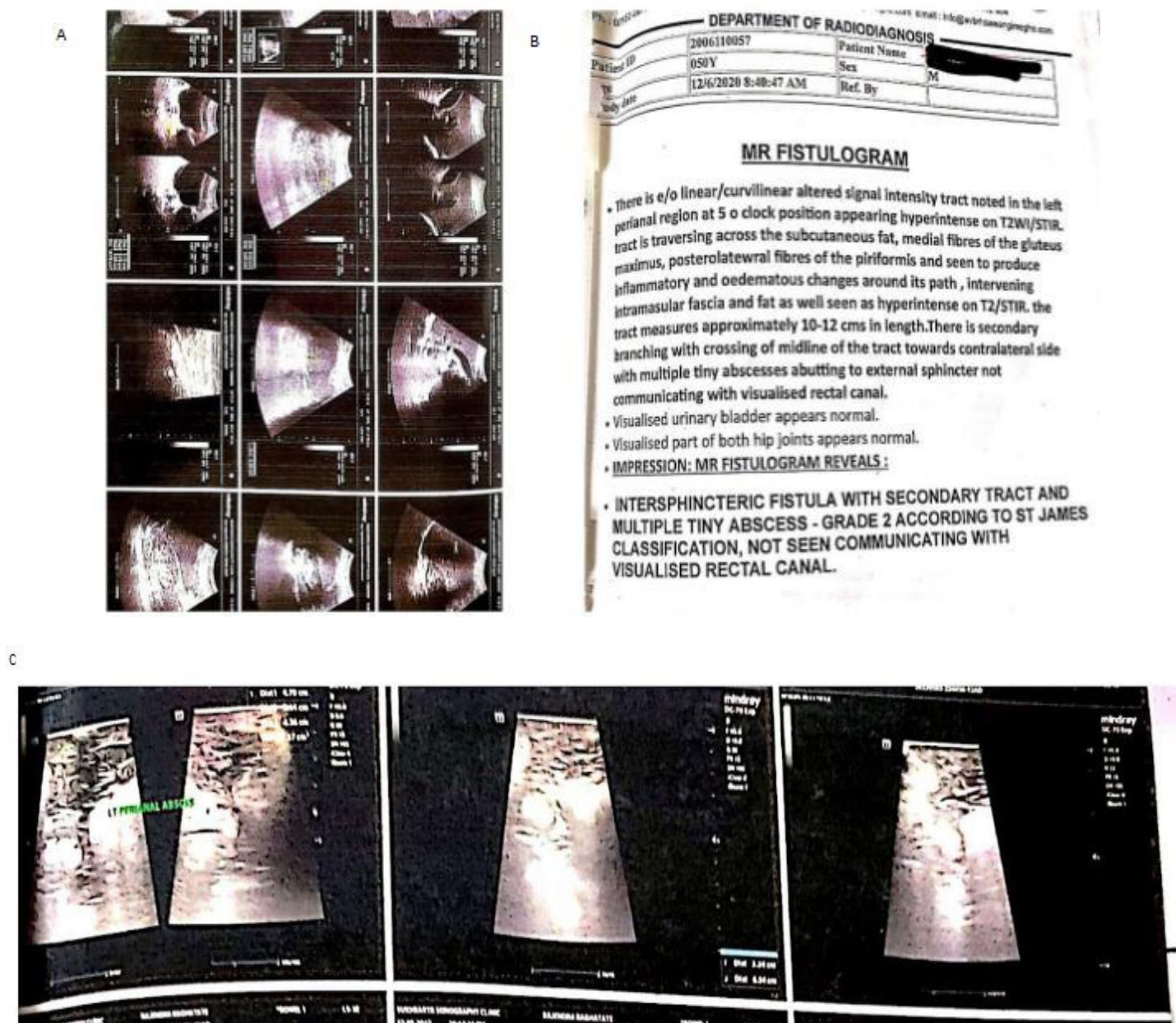
Localized Horseshoe induration and fluctuation in parts, Raised local temperature, Pain +++

### 2.11. Per rectal examination

Sphincter spasm grade I

### 2.12. Surgical Investigation

Hematological Test- Hb- 11.3gm%, TLC- 16400/cu mm, DLC- N-86%, L-13%, E-1%, B-0%, M-0%, Total RBC's- 4.06millions, Platelets- 263000, ESR- 85mm/1<sup>st</sup> hour, RBS- 184mg%, LFT-WNL, KFT- GROSSLY DERANGED, Urine-R, M-Albumin +, Pus cells-2-3/hpf, RBCs- 2-3/hpf, Casts & crystals- Absent, Epithelial cells- Occasional, Bacteria- Present



**Fig 1-A: 1<sup>st</sup> is USG Abdomen, 2<sup>nd</sup> is MRI Fistulogram, and 3<sup>rd</sup> picture is Perianal USG which reveals that in USG ABDOMEN 14/6/2020- Small sized both kidneys (right>left) with features of Chronic medical renal parenchymal changes Grade 2. B: MRI FISTULOGRAM 12/6/2020-Intersphincteric fistula with secondary tract and multiple tiny abscess Grade 2. C: USG ABDOMEN 14/6/2020- Small-sized both kidneys (right>left) with features of Chronic medical renal parenchymal changes Grade 2**

### 2.13. Diagnosis

Perianal abscess 3-8'o'clock with High Anal Intersphincteric Fistula in Ano.

### 2.14. Prognosis

The patient was in Sepsis condition, oliguria with a poor prognosis.

### 2.15. Treatment Plan

(Conservative treatment) 4/5/2022

### 2.16. Pre-operative medication

Inj Piptaz 4.5gm IV BD After food, IV Metrogl 100ml TDS After food, Inj Pan 40mg OD Before food, IV Fluids- DNS, RL, NS 20 drops/min 4 hourly given for 24 hours. On 5/5/2022, it was observed that his General condition was moderate, BP- 80/60mmHg, Temp- 97degree F, Urine Void- 3 times concentrated, from Morning to 4 pm, so Foley's catheter (14 no) was inserted on 5/5/2022 for monitoring 24 hours' urine output. Unfortunately, it was the condition of Septic shock which was managed successively. Also, the Patient's KFT was grossly deranged; hence he was posted for Surgery under Local Anesthesia.

### 2.17. Preparation of Ksheera sutra

Early morning fresh ksheera from the Udumber tree is collected and coated in Barber's thread no 21. And the thread is kept in

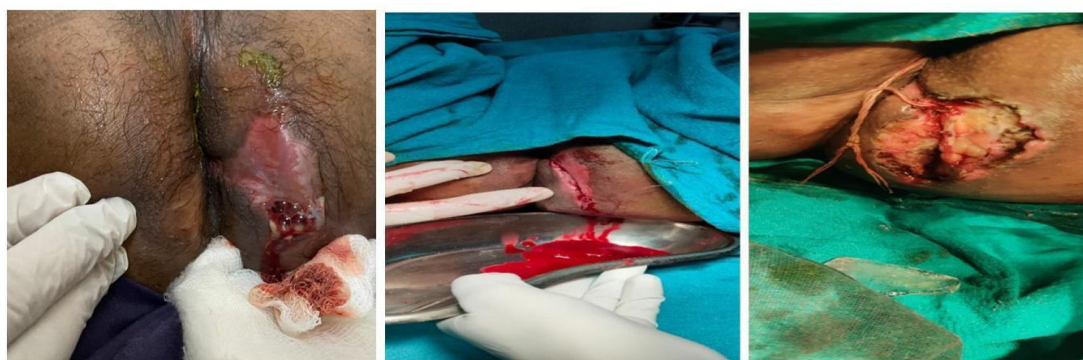the box before the light for drying. Similar coatings till 21 days are done. And then, the *ksheerasutra* is used in this case.

## 2.18. Pradhana karma (Operative procedure) 06/05/2022

## 2.19. Procedure- Incision and Drainage with Ksheersutra application

Under all aseptic precautions under Local Anaesthesia, cleaning and draping of the part at the lithotomy position are done. From the burst abscess at 3'0'clock position, pus drained,

Incision deepened, pus pockets drained, loculi broken by using fingers. Pus collected for culture and sensitivity. Probing was done from the 3'0'clock position, and the internal opening was located at 5 to 6 0 clock position in the anal canal above the dentate line. *Ksheerasutra* ligation was done. Surrounding fibrosed tissues, the abscess cavity was debrided, and the sample was sent to an osteopath. The cavity was cleaned with Betadine +H<sub>2</sub>O<sub>2</sub>+ NS; Complete hemostasis was achieved. Packing of the abscess cavity was done with Betadine gauze and bandaging. The patient was shifted to the ward in normal condition. The procedure could have been more uneventful.



**Fig 2: In the first picture, there is a burst boil with bloody discharge; in the 2<sup>nd</sup> picture, Incision and drainage are done; in the 3<sup>rd</sup> picture, after Incision and drainage, the fibrosis skin was debrided, probing was done and Ksheer sutra ligation is done.**

## Post-operative Treatment

### POD-0

1. NBM for 4 hours after the procedure.
2. Iv fluid NS-500ml and RL-500ml 20 drops/min alternatively (total 5fluids)
3. Inj Piptaz-4.5gm IV BD in 100ml NS After food
4. Inj Pan- 40mg OD Before food
5. IV Metrogyl 100ml TDS After food
6. Inj Ondem-8mg SOS
7. Inj Tramadol in NS- SOS, After this sample was given for the following test- CBC, S. Urea & Creat, FBS, PPBS, Urine R, M Antibiotic culture & sensitivity.

### POD-I

- I/O - 5000ml /2100ml
- GC- moderate
- BP- 100/70mmHg
- P-70min
- Chest-S1S2 heard, AE=BL
- Bowel- clear
- A soft diet was given
- The same treatment was carried out
- Sitz Bath with Hot water BD
- Dressing- By Ksharataila Pooran

### L/E

1. Cleaning of the wound with Betadine done
2. Sloughs present were removed
3. Mild active bleeding
4. Thread in situ
5. Betadine roller gauze packing is done.
6. Bandaging done



**On Microbiology report**

Growth of E coli was reported, and on culture and sensitivity report-Sensitivity to Amikacin, Amoxyclav, Aztreonem, Cotrimoxazole, Gentamycin, Meropenem, Piperacillin/Tazobactam was reported. Accordingly, medication was given.

**POD-2 ( 8/5/2022)**

C/O-

- Mild Pain at the operated site
- Generalized weakness
- Bilateral pedal edema +, Soft diet
- Inj Cefotaxime-1gm IV BD After food
- Inj Pan-40mg IV OD Before food
- IV Metrogyl -100ml TDS After food
- Inj Tramadol-50mg/2cc in 100ml NS
- IV Fluids- DNS, RL, NS 20drops/min (5fluids)
- Tab Chlorthiazide- 12.5mg I OD
- Syp Laxan 30ml HS
- Sitz bath with hot water BD

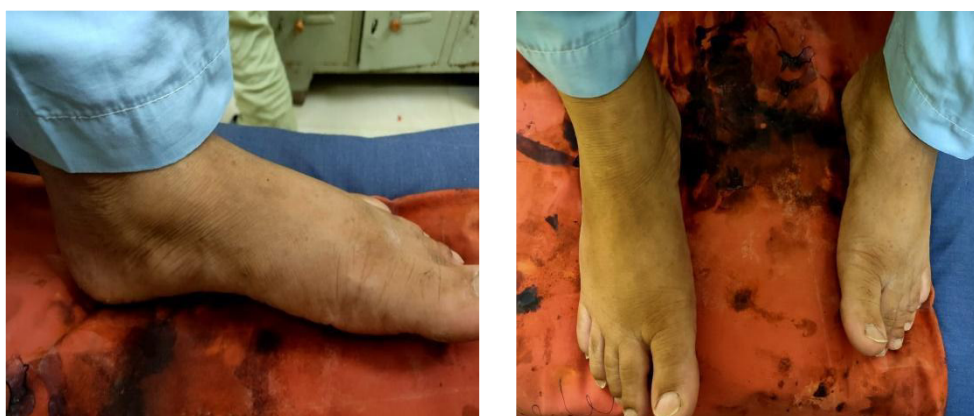O/E-

**Foley's Catheter- D4**

- I/O-2700ml /I 250ml
- GC- Moderate
- BP-100/60mmHg
- P-76/min
- CVS-NAD
- Chest- AE=B/L
- Bowel-clear
- P/A- soft

**Dressing**

- Cleaning done.
- Sloughs removed
- *Kshar taila pooran* in Roller gauze
- Xylocaine jelly locally in the margins of the wound applied.
- Thread in Situ.



**Fig 3: Mild Pedal edema was present.**

**POD-4 10/05/2022**

C/O-

- Mild Pain at the operated site
- B/L pedal edema slightly reduced

Rx-

1. A normal diet was started from 3<sup>rd</sup> day
2. 5 IV Fluids over 24 hours, MVI in DNS
3. Tab Metrogyl ER-600mg 1 BD after food
4. Tab Cefibact 200mg 1 BD After food
5. Tab Pan 40mg 1 OD Before food
6. Tab Ultracet 1 SOS after food
7. Tab Neeri 1 BD After food
8. Cap Becosules - 1 BD After food 15 days
9. Tab Limcee-1 OD After food

6 days

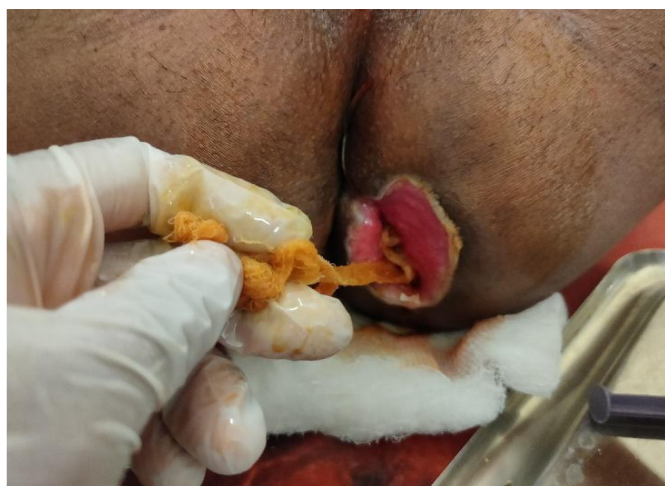

Fig 4-Kshara Taila Pooran by Gauze

| Table I- Detail of Medications Provided according to the Post-Operative complaints |  |                       |             |           |                    |                                     |   |  |
|--|--|-----------------------|-------------|-----------|--------------------|-------------------------------------|---|--|
| POD  | Complaints   | Vitals and I/O Access |             |           |                    | L/E                                 | Specific treatment  | Dressing   |
| 5 <sup>th</sup><br>11/5/22   | Mild pain at the operated site, vomiting 1 episode | BP<br>120/80          | P<br>60/min | T<br>97 F | I/O<br>3850/2750ml | Serous followed by bloody discharge | Ct all<br>Inj Perinorm IV given<br>Tab chlorothiazide       | Kshara taila puran done  |
| 6 <sup>th</sup><br>12/5/22   | Mild pain remained                                 | 110/70                | 72/min      | 97.6 F    | 4500/2900ml        | Same                                | Same  | Same   |
| 7 <sup>th</sup><br>3/5/22  | Mild pain during dressing only                     | 120/80                | 76/min      | 95        | 5000/2950ml        | Wound margins intact                | Same<br>Encouraged oral fluids<br>Tab chlorothiazide given  | Same<br>KS change done<br>Under AAP, Foley's catheter was removed. Urination checked approx. 200ml |
| 8 <sup>th</sup><br>14/5/22   | Relief from pain                                   | 130/90                | 70/min      | Afeb      | 3000/2000ml        | Pus discharge from the cavity       | Tab Clavum 625mg TDS AF started<br>Tab Cefibact stopped     | Panchavalkal ointment dressing started   |
| 9 <sup>th</sup><br>15/5/22   | No pain  | 120/80                | 74/min      | 98        | 4500/4050ml        | Mild pus discharge                  | Tab chlorothiazide given<br>Rest same                       | Same   |
| 10 <sup>th</sup><br>16/5/22  | No fresh complaints                                | 130/90                | 74/min      | 97        | 4300/3900ml        | Pus discharge                       | Tab Chymoral forte ITDS started                             | Same   |
| 11 <sup>th</sup><br>17/5/22  | Vomiting 1 episode at 3 am                         | 130/90                | 78/min      | 98.1 f    | 4500/4100ml        | Pus discharge mild                  | Tab chlorothiazide given<br>Tab Metrogyl-0 400mg BD Started | Same   |

|                             |                        |        |        |      |             |  |   |                              |
|-----------------------------|------------------------|--------|--------|------|-------------|--|---|------------------------------|
|                             |                        |        |        |      |             |  | Tab Metrogl ER<br>Stopped   |                              |
| 12 <sup>th</sup><br>18/5/22 | No fresh<br>complaints | 110/70 | 70/min | Afeb | 4650/3950ml | Same                                       | Triphala Guggulu<br>2BD<br>Tab Gandhak<br>Rasayan 2BD<br>started AF   | Same                         |
| 13 <sup>th</sup><br>19/5/22 | No fresh<br>complaints | 120/90 | 70/min | Afeb | 4200/3500ml | Pus sent for<br>culture and<br>sensitivity | Trikatu churna 3gm<br>with honey BD For<br>5 days<br>Ajmodadi churna<br>3gm with kosha<br>Jala BD BFstarted<br>for Deepana<br>pachana | Same                         |
| 14 <sup>th</sup><br>20/5/22 | No fresh<br>complaints | 130/90 | 78/min | Afeb | 4500/3300ml | Same                                       | Same  | KS change<br>done            |
| 15 <sup>th</sup><br>21/5/22 | No fresh<br>complaints | 120/70 | 73/min | Afeb | 4350/3200ml | Healthy<br>granulation                     | Syp Neeri KFT<br>10ml BD AF started   | Same<br>Advised<br>Discharge |

This table contains all the relevant treatment days and their overall observations. From postoperative day 5, his vitals came out to be almost normal, and I/O access came out to be sufficiently better, but still, the output was low; for that, Diuretics were administered. Along with that, regular dressing was given. The 7<sup>th</sup> catheter was removed on the day, and the patient was completely under oral diet and oral medications. His vitals were maintained until they arrived normal, and on the 15<sup>th</sup> day, he was advised of discharge.

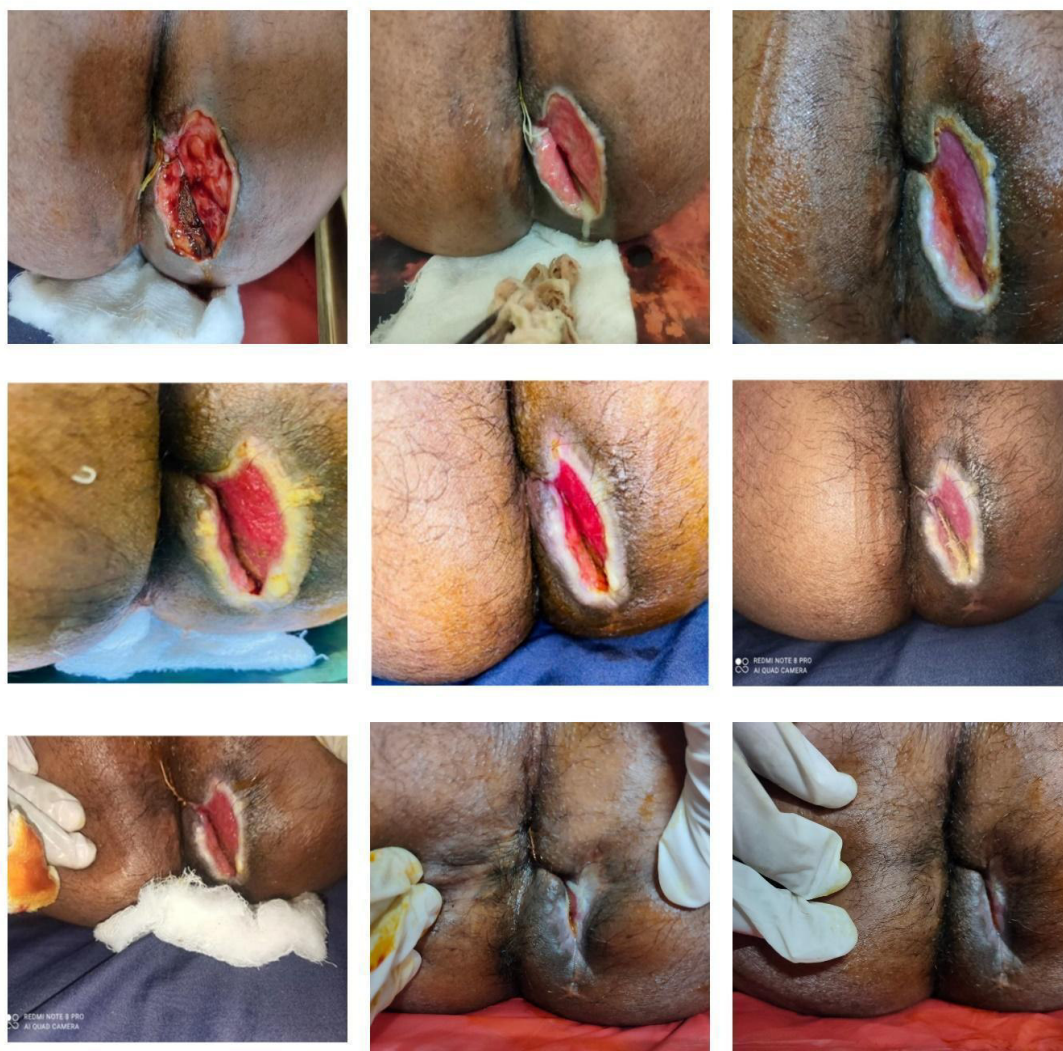#### On discharge Medication

- Tab Triphala guggulu<sup>6</sup>- 2BD After food with lukewarm water
- Tab Gandhak Rasayan<sup>7</sup>- 2BD After food
- Syrup Neeri KFT<sup>8</sup>- 10ml BD After food
- Cap Becosules 1BD After food
- Tab Limcee 500mg 1BD After food
- Kshara taila pooran<sup>9</sup>
- Panchavalkal ointment<sup>10</sup> dressing
- Sitz bath with hot water BD

| Table 2- Observation of Reports Before & During the Treatment |                               |         |            |        |               |                                  |
|---|-------------------------------|---------|------------|--------|---------------|----------------------------------|
| Date  | RBS/FFBS                      | Hb%     | TLC        | S.Urea | S. Creatinine | Urine R/M                        |
| 5/5/22  | 183mg/dl                      | 11.3gm% | 16400/cumm | 78mg%  | 3.50mg%       | Albumin +                        |
| 7/5/22  | RBS- 88mg/dl                  | 9gm%    | 5100/cumm  | 42mg%  | 2.5mg%        | Albumin –<br>Pus cells 10-12/hpf |
| 11/5/22   | FBS- 95mg/dl<br>PPBS-103mg/dl | 10.4gm% | --         | 14mg%  | 2.3mg%        | --                               |
| 14/5/22   | --                            | --      | --         | 13mg%  | 2.2mg%        | --                               |
| 18/5/22   | --                            | --      | --         | --     | 2.3mg%        | --                               |
| 21/5/22   | --                            | --      | --         | --     | 2.4mg%        | --                               |
| 1/6/22  | --                            | --      | --         | 23mg%  | 1.8mg%        | --                               |
| 15/6/22   | --                            | --      | --         | 27mg%  | 1.4mg%        | NIL                              |

This table contained information on Hematological information when the patient was admitted and his improvements during the treatment. There were gross changes in the TLC counts before and after the treatment and in the Urea and creatinine levels. On 24/5/2022, USG KUB was

advised, which reported Mild echogenicity raised in Kidney, and the parenchymal renal changes observed in the previous USG were normal. In addition, a normal urinary bladder with no evidence of calculus or mass was seen. Therefore, it proves that there was an improvement in Kidney too.



**Fig 5 contains 9 pictures of the post-operative care from 11/5/2022 to 27/7/2022. In this wound, size was observed with cutting and healing of the fistular track with thread. In the recent few days, pus was discharged from the abscess cavity, which was washed with Betadine+ Hydrogen peroxide +Normal saline. Then Kshara taila was poured into the cavity, and outer packing in the wound was given by Panchavalka ointment. On every 7<sup>th</sup> day, Ksheersutra was changed. Every week, there was an improvement in the granulation of the wound with a decrease in wound size and healing.**

### 3. DISCUSSION

The patient had recurrent perianal abscess and fistula in an associated with co-morbidities hypertension and Chronic kidney disease. The patient had undergone Surgical management thrice and was distressed mentally. He was on various medications for the past two years due to his associated co-morbidities. He was under a High dose of Antihypertensive medication and diagnosed with CKD by the doctors he consulted earlier; his condition was so poor, So he was declared unfit for surgery, which was the prime management required at that time. He was severely uncomfortable and had signs of dehydration, profuse blood, and pus discharge. He was given immediate medical intervention, including IV fluid management, to treat his dehydration status, and was put on broad-spectrum antibiotics as pre-surgical prophylaxis. He positively responded to the treatment and was still unfit for Anaesthesia hence taken for Surgery on the third day. Incision and drainage were done along with debridement of fibrotic tissues, and Ksheer sutra was applied. His general condition can be seen as his vitals, including BP of 80/60mm Hg during admission, improved to

120/80 mm Hg. The patient was not very coordinative with food and liquid intake. So was instructed IV Fluids, and his I/O access was examined 24hourly. His vitals comes out to be improving day by day (Table-1). Wound management was done twice daily with Panchavalka ointment and Kshar taila. Good granulation was achieved, along with rapid filling of the wound cavity. Improvement in TLC Count is visibly noticed along with his deranged Urea; Creatinine levels appear almost near to normal during his complete course of treatment. His pedal edema was completely cured, and urine output levels showed remarkable improvement in his renal status (Table-2). During the complete course of treatment, the patient has been advised a diet that includes green vegetables, and fruits, with plenty of fluids, and a completely balanced diet and instructed not to consume spicy, oily, junk food, or alcohol. Also was advised to avoid long sitting and riding or traveling during treatment. Appropriate antibiotics controlled the utmost emergency management for Infection and Compromised kidney functions; later on, adjuvant therapy for nephroprotection and to enhance healthy kidney functions is continued with Neeri KFT. The concept was based on the version given by Chakradutta on Ksharasutra preparation. It is



difficult to depend solely upon *Apamarga* because of its limited global availability. Hence, to develop an alternative to *Apamarga Kshara Sutra* <sup>14</sup>in view of easy processing, *Udumber Ksheera Sutra* without any *Kshara*. The patient is still on *Udumber Ksheera* <sup>11,15</sup> sutra application once every week, in which we have observed remarkable cutting and healing on the fistular tract. *Panchavalkal Ointment* <sup>12</sup>having properties. *Kashaya Ras* acts in *Vrana Ropana* and *Shodhana* property of the abscess cavity. It is *rooksha* and *kaphahara*, *lahara*, and *raktashodhaka* that help in the debridement of sloughs. And promotes the healing of the wound. Anti-inflammatory action- With the help of chemical constituents like Tannins, and flavonoids of *Vata*, *Udumber*, and *Ashwath*, it has pharmacological action against inflammation. Tannins, phytosterols, and flavonoids are anti-inflammatory. *Apamarga Kshara taila* <sup>13,16,17</sup> due to *kshara guna* does *chhedan*, *bhedana*, and *lekhana* activity helps heal abscess cavity. *Tab Gandhak Rasayan* helped treat infection owing to its potent antibiotic trait, enhancing the body's strength by stimulating digestion. *Gandhaka Rasayan Vati* ingredients have *kandughna*, *kushthaghna*, *dahanashak*, *raktaprasadan*, and *Agra visa doshaghna* properties.

#### 4. CONCLUSION

The patient was done rigorous counseling during the entire treatment process, and timely and appropriate management helped to save the patient's life from the life-threatening complications of the grave condition of Peri-anal abscess converted to fistula with impending Renal failure. *Kshara sutra* is well known for any unhealthy tract's *kshanan* and *ksharan*

activity. In this case, after the surgical procedure of Incision & drainage, the patient is shifted to Ayurvedic *ksheera sutra*, at this moment explains the efficacy of *Ksheera sutra* in the post-operative perianal abscess condition where the fistular track is ligated with *ksheera sutra* and weekly changing is done till complete cutting and healing of the track. In this way, combining holistic and integrated approaches helped the patient get cured of the disease and lead a normal life.

#### 5. DECLARATION OF PATIENT CONSENT

The authors certify that they have obtained all appropriate patient consent forms. In the form, the patient has consented for his images and other clinical information to be reported in the journal.

#### 6. AUTHOR'S CONTRIBUTION STATEMENT

Complete Surgical and medical treatment, Ward management for the patient in IPD, his regular dressings, along with keeping the record and data collection and Compiling the data into case format is done by Shreya Soni and Sandeep Kumar Upadhyay under the guidance of Dr Sheetal Asutkar. Regular follow-up during the complete treatment and technical skills for the proper formatting of the reports are done by Yogesh Yadav. All this was under the complete guidance of my HOD, Dr. Sheetal Asutkar.

#### 7. CONFLICT OF INTEREST

Conflict of interest declared none.

#### 8. REFERENCES

1. Abcarian H. Anorectal infection: abscess-fistula. Clin Colon Rectal Surg. 2011 Mar;24(1):14-21. doi: 10.1055/s-0031-1272819, PMID 22379401.
2. Sainio P. Fistula-in-ano in a defined population. Incidence and epidemiological aspects. Ann Chir Gynaecol. 1984;73(4):219-24. PMID 6508203.
3. Samhita S (Purvardh and Uttarardh). Ambika Dutta Shastri, Chikitsa Sthana Ch.16, Verse. 35-37. Varanasi: Chaukhambha Sanskrit Sansthan, 2009.p. 97-8.
4. Sharma PV. Chakradata: Chikitsasthan. Arshachikitsaprakranadhayayam. 1st ed. Varanasi: Chowkhambha Publisher; 2007. p. 87.
5. Mishra BS. Bhavprakash: madhya khanda. Arshoadhikaradhayayam. 11th ed. Chowkhambha Sanskrit Bhavan, 2007, Varanasi. p. 66.
6. Meena RK, Dudhamal T, Gupta SK, Mahanta V. Comparative clinical study of Guggulu-based Ksharasutra in Bhagandara (fistula-in-ano) with or without partial fistulectomy. Ayu. 2018 Jan-Mar;39(1):2-8. doi: 10.4103/ayu.AYU\_19\_15, PMID 30595627. PMCID PMC6287408.
7. Joshi Y.G. textbook of kayachikitsa, chapter no. 79. pune: Shri Ganesh publisher; 2010. p. 651.
8. Gautam G, Parveen B, Khan MU, Sharma I, Sharma AK, Parveen R, Ahmad S. A systematic review on nephron protective AYUSH drugs as constituents of NEERI-KFT (A traditional Indian polyherbal formulation) for the management of chronic kidney disease. Saudi Journal of Biological Sciences. 2021 Nov 1;28(11):6441-53.
9. Gohil H, Dhruve K, Prajapati PK. Role of media in the preparation of *Apamarga Ksharataila*. Ayu. 2010;31(3):391-4. doi: 10.4103/0974-8520.77158, PMID 22131746.
10. Meena Rk, Dudhamal t, Mahanta V. Wound healing potential of Panchavalkala formulations in postfistulectomy wound.
11. A Role of Udumbara ksheer Sutra in anorectal Fistula: an Ayurvedic Review. Int J Ayurveda Pharm Res;10(1):98-102.
12. shukla3http://www.ayujournal.org. A Clinical study on the efficacy of Panchavalkal cream in vrana shodhana w.s.r to its action on microbial load and wound infection,k shobha Bhat,vishwesh b.n.;I, manoranjan sahu2,vijay kumar.
13. Chakrapani C, Karnaroga. Varanasi: Chaukhambha Sanskrit Sansthan; 2005. p. 339.
14. Lobo SJ, Bhuyan C, Gupta SK, Dudhamal TS. A comparative clinical study of Snuhi Ksheera Sutra, Tilanala Kshara Sutra and Apamarga Kshara Sutra in Bhagandara (Fistula in Ano). Ayu. 2012;33(1):85-91. doi: 10.4103/0974-8520.100319, PMID 23049190.
15. Kumar A, Yadav S, Yadav AK. A role of Udumbara ksheer Sutra in ano rectal fistula: an ayurvedic review [international journal] of Ayurveda and Pharma Research. 2022;10(1):98102. doi: 10.47070/ijapr.v10i1.2173.
16. Joshi F, Dudhamal TS. Tissue Debridement effect of apamarga kshara taila and adjuvant medications in the management of nonhealing venous ulcer: A case series. Med J DY Patil Vidyapeeth. 2021;14(5):549-53. doi: 10.4103/mjdrdypu.mjdrdypu\_52\_20.