




## Dentinogenesis Imperfecta Associated with Hypophosphatemic Rickets- A Report of the Rarest Case

Dr. Ramhari Sathawane<sup>1</sup>, Dr. Ashish Lanjekar<sup>2</sup>, Dr. Isha Madne<sup>3\*</sup> , Dr. Pranada Deshmukh<sup>3</sup>,  
Dr. Zareesh Akhtar<sup>3</sup>, Dr. Charwak Tayade<sup>3</sup>, Dr. Komal Deotale<sup>3</sup> and Dr. Raksha Jaiswal<sup>3</sup>

<sup>1</sup> Professor and Head, Department of Oral Medicine and Radiology, Swargiya Dadasaheb Kalmegh Smruti Dental College and hospital, Nagpur.

<sup>2</sup> Reader, Department of Oral Medicine and Radiology, Swargiya Dadasaheb Kalmegh Smruti Dental College and hospital, Nagpur.

<sup>3</sup> PG Student, Department of Oral Medicine and Radiology, Swargiya Dadasaheb Kalmegh Smruti Dental College and hospital, Nagpur.

**Abstract:** Rickets is a childhood bone disorder. It is caused due to deficiency of Vitamin D, calcium, and phosphate. Bones become soft and weak and are prone to fracture due to inadequate intake of these nutrients. Rickets result from abnormalities of the growth plate cartilage predominantly affecting longer bones and leading to poor bone growth, defective mineralization, and bony deformities such as bow legs and knock-knees. This case report presents a rare case of a 21-year-old female patient with discoloration and abnormalities of teeth since childhood with hypophosphatemic rickets in early childhood who suffered from subsequent loss of tooth structure and bone deformities. Orthopantomogram revealed bulbous crowns of teeth with cervical constriction, obliterated pulp chambers, and slender roots. X-ray chest revealed decreased costochondral angle suggestive of pigeon chest. Serum calcium and Vitamin D were, but serum phosphorus levels were decreased. The patient was examined by a Physician & Orthopedic Surgeon. On the basis of clinical-radiographic features and serum biochemistry findings, this case was diagnosed as Dentinogenesis Imperfecta associated with Hypophosphatemic Rickets.

**Keywords:** Rickets, Deficiency of Vit. D, Calcium and Phosphate, Dentinogenesis Imperfecta and Hypophosphatemic Rickets

---

### \*Corresponding Author

Dr. Isha Madne, PG Student, Department of Oral  
Medicine and Radiology, Swargiya Dadasaheb Kalmegh  
Smruti Dental College and hospital, Nagpur.

Received On 6 June, 2022

Revised On 18 November, 2022

Accepted On 29 November, 2022

Published On 1 March, 2023

---

### Funding

This research did not receive any specific grant from any funding agencies in the public, commercial or not for profit sectors.

### Citation

Dr. Ramhari Sathawane, Dr. Ashish Lanjekar, Dr. Isha Madne, Dr. Pranada Deshmukh, Dr. Zareesh Akhtar, Dr. Charwak Tayade, Dr. Komal Deotale and Dr. Raksha Jaiswal, Dentinogenesis Imperfecta Associated with Hypophosphatemic Rickets- A Report of the Rarest Case.(2023).Int. J. Life Sci. Pharma Res.13(2), P78-P82 <http://dx.doi.org/10.22376/ijlpr.2023.13.2.P78-P82>

This article is under the CC BY- NC-ND Licence (<https://creativecommons.org/licenses/by-nc-nd/4.0>)

Copyright © International Journal of Life Science and Pharma Research, available at [www.ijlpr.com](http://www.ijlpr.com)



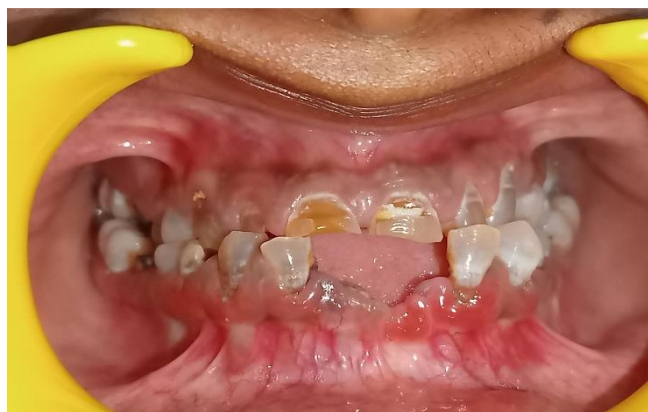## I. INTRODUCTION

Phosphate is one of the most important molecular elements required for normal cellular functions within the body. It acts as an integral component of nucleic acid and is used to replicate DNA and RNA. It adds and deletes phosphate groups to or from proteins, and functions as an "on/off" switch to regulate molecular activity.<sup>1</sup> Given its widespread role in nearly every molecular, and cellular function, aberrations in serum phosphate levels can be highly impactful. Hypophosphatemia is defined as an adult serum phosphate level of less than 2.5 mg/dL. The normal serum phosphate level in children is considerably higher and 7+-1.3 mg/dL for infants. Hypophosphatemia is an uncommon laboratory abnormality and is often an incidental finding.<sup>2</sup> Phosphate is also required for proper bone growth and for tooth mineralization<sup>3</sup>. Its deficiency during gestation affects primary teeth, whereas during early childhood it affects permanent teeth. Rickets has a significant impact on a child's or adolescent's overall health, growth, and development. Dentinogenesis imperfecta (DI) is described as a localized form of mesodermal dysplasia observed in histodifferentiation and corresponds to a congenital hereditary change involving deciduous and permanent teeth. Talbot was the first to describe DI as an autosomal dominant characteristic. The name DI was coined by Roberts and Schonr, who described it as a disease comparable to Osteogenesis Imperfecta (OI). It has a

straightforward autosomal dominant inheritance pattern with great penetrance and a modest mutation rate<sup>4</sup>. Shields et al proposed three types of dentinogenesis imperfecta: DI type 1 is associated with osteogenesis imperfecta. DI type 2 has essentially the same clinical radiographic and histological features as DI type 1 but without osteogenesis imperfecta; DI type 3 is rare and is only found in the tri racial Brandywine population of Maryland.<sup>5</sup> The rare case of Dentinogenesis Imperfecta associated with Hypophosphatemic Rickets is reported and discussed with its etiopathogenesis, clinical features, investigations, diagnosis, and management

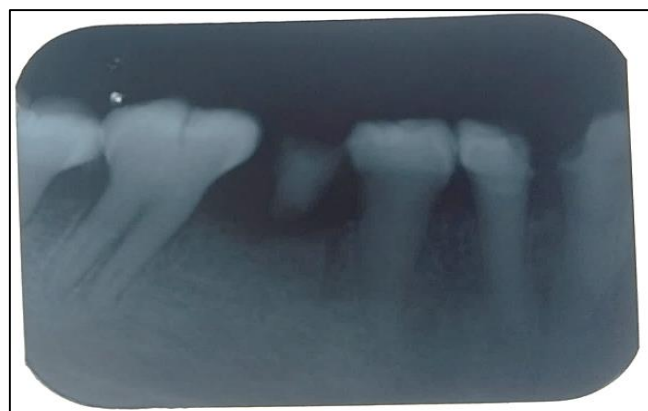## 2. CASE REPORT

A 21-year-old female reported to the department with the chief complaint of discoloration of teeth since childhood and loosening of upper and lower teeth in the right back region of jaw for 2 -3 years. Her past medical history revealed that she had fractured her left femur twice in childhood due to slight trauma. Her was asthenic with a height of 4.7 feet. General physical examination revealed that she had a pigeon chest (pectus carinatum) and bowing of legs with short stature. On intraoral examination, generalized brownish and greyish opalescent teeth were seen with erythematous lower gingiva, root piece with 46; missing teeth 31,41; Grade I mobility with 24, 25 ,45; Grade II mobility with 16 ,26 and generalized attrited teeth were present (fig.1)

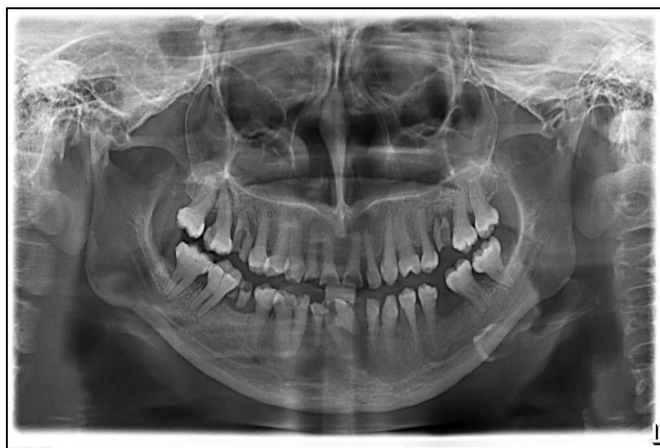

**Fig 1: Clinical photograph showing multiple attrited opalescent teeth and erythematous gingiva**

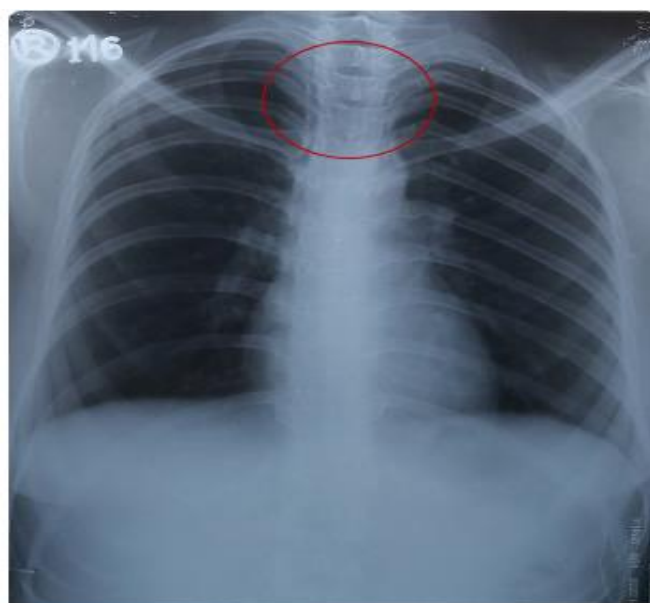
Intraoral periapical radiograph with 46 and Orthopantomogram (OPG) revealed bulbous crown with cervical constriction, obliterated pulp chambers and slender roots (fig. 2 and 3). X-ray chest revealed decreased costochondral angle suggestive of a pigeon chest (fig. 4). X-ray femur showed splaying of femoral bone, marginal sclerosis on the distal femur, and increased cortical thickening (fig 5).



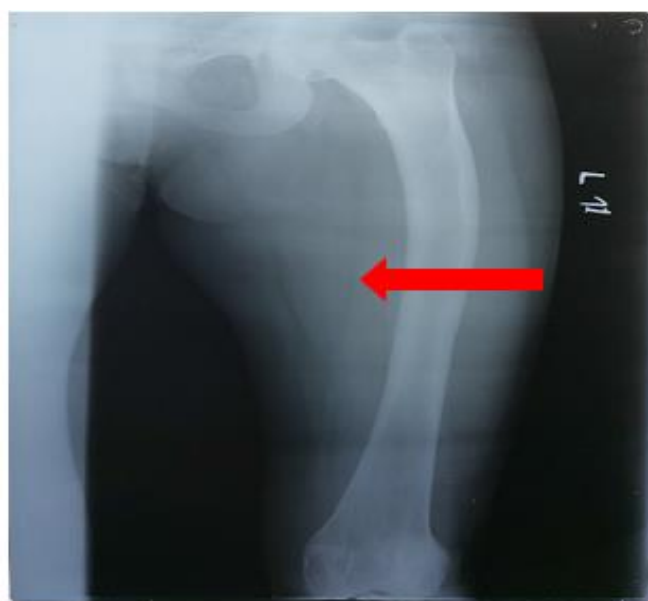**Fig. 2: Periapical radiograph showing bulbous crown, cervical constriction, obliterated pulp and slender roots in case of dentinogenesis imperfecta**



**Fig. 3: OPG showing bulbous crown, cervical constriction, obliterated pulp and slender roots**

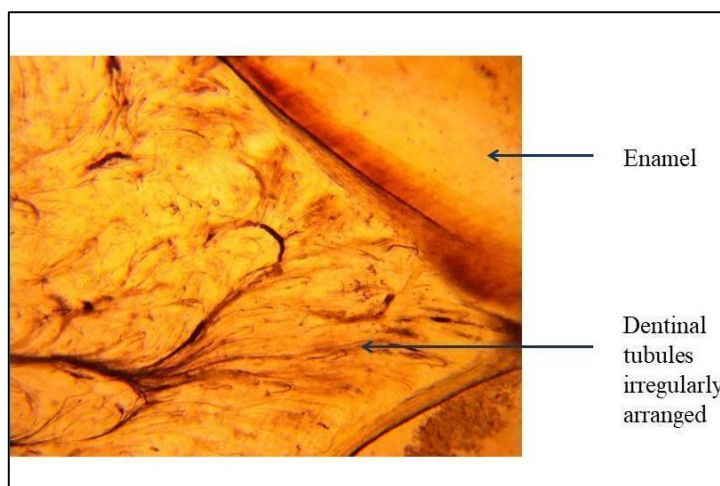


**Fig 4: X-Ray Chest showing decreased costochondral angle suggestive of pectus carinatum**



**Fig 5: X-ray femur showing splaying of femur and cortical thickening**

The ground section of the tooth showed a regular arrangement of enamel rods and irregular arrangement of dentinal tubules with few large dentinal tubules. The root portion showed dentin with the irregular arrangement and a few large dentinal tubules.



**Fig. 6: Ground section of tooth showing the irregular arrangement of dentinal tubule with few large dentinal tubules**

Her blood investigations revealed normal levels of serum calcium and Vitamin D, elevated levels of alkaline phosphatase, and serum phosphorus levels declined. Based on clinical, radiological, and hematological findings the patient was diagnosed as a case of Hypophosphatemic Rickets. Dentinogenesis Imperfecta was diagnosed from clinical and radiographic findings and confirmed on ground section findings so, the patient was diagnosed as case of Dentinogenesis Imperfecta associated with Hypophosphatemic Rickets.

### 3. DISCUSSION

Bone and dentin are both mineralized tissues with similar compositions and formation mechanisms.<sup>6</sup> They're both made up of a mineral phase of carbonate-substituted hydroxyapatite (HAP) crystals and an organic matrix rich in type I collagen. Mineralization happens in several stages during osteogenesis and dentinogenesis. The main formative cell types of bone and dentin, osteoblasts and odontoblasts, secrete a non-mineralized matrix called osteoid and predentin, respectively. The primary protein of predentin and osteoid ECM, type I collagen, is gradually assembled into fibrils to produce a well-organized matrix that serves as a framework.<sup>7</sup> At the mineralization front, calcium and phosphate ions transported from the vascular network mineralize the matrix. Dentinogenesis Imperfecta is a form of localized mesodermal dysplasia that affects both the primary and permanent teeth.<sup>8</sup> Dentin deficiencies are usually autosomal dominant, but there have been reports of autosomal recessive and X-linked cases of dentin defects associated with syndromes. Osteogenesis imperfecta (OI), Ehlers-Danlos syndrome (EDS), tumoral calcinosis, and hypophosphatemic rickets are only a few of the disorders that have dentin abnormalities<sup>9</sup>. Dentinogenesis Imperfecta is a genetic condition that affects dentin. This deficiency is caused by a mutation in the dentin sialoprophosphoprotein (DSPP). The DSPP gene is found in a cluster of dentin and bone matrix genes at 4q21.3. Dentin sialoprotein (DSP) and dentin phosphoprotein (DPP) are encoded by DSPP as a single precursor protein that is cleaved before secretion. In dentinogenesis, DSP and DPP play separate functions. DPP is a mineralization nucleator that causes the development of apatite<sup>10</sup>. The color of teeth varies from brown to blue, sometimes described as amber or gray, with an opalescent sheen, which was also evident in our case. In about one-third of patients, the enamel may display hypoplastic or hypocalcified flaws, and it tends to crack away from the

deficient dentin. The exposed dentin may be subjected to quick and severe attrition. The teeth exhibit bulbous crowns with cervical constriction and thin short roots on radiographs. Pulp chambers may appear excessively broad at first, resembling "shell teeth," but they will gradually disappear. Similar features were seen in the present case. Histologically, the enamel, although normal in structure, tends to crack. There is no scalloping at the Dentinoenamel Junction (DEJ). The enamel rods right above the DEJ appear to be faulty, with minor hypo calcification flaws. Although it appears qualitatively normal, the DEJ appears flattened<sup>8</sup>. Albright and collaborators first defined hypophosphatemic rickets as vitamin D-resistant rickets in 1937.<sup>11</sup> Later, many types of hypophosphatemic rickets were discovered, based on the type of inheritance (X-linked, autosomal, recessive, or dominant) and the gene mutation. The X-linked variant is the most common type. PEX (phosphate regulating gene with homologies to endopeptidases on the X-chromosome) was found as the primary cause of X-linked (79 percent) dominant hypophosphatemic rickets in 1995 (MIM 300550). (MIM 307800).<sup>12</sup> Autosomal dominant hypophosphatemic rickets is caused by mutations in FGF23, while autosomal recessive hypophosphatemic rickets is caused by mutations in DMP1 and SLC34A.<sup>13</sup> Hypophosphatemic rickets has recently been linked to loss-of-function mutations in the ENPPI gene and a translocation involving the Klotho gene.<sup>14</sup> The PHEX gene encodes a 749 amino acid transmembrane endopeptidase and is found on chromosome Xp22.1–22.2 in humans. Osteoblasts, osteocytes, and odontoblasts all express PHEX, which is involved in calcium and phosphate metabolism<sup>15</sup>. The phenotype of X-linked dominant hypophosphatemic rickets (XLHR) is defined by leg bowing, short stature, high bone mass, severe dental anomalies, increased alkaline phosphatase activity, hypophosphatemia due to renal tubular phosphate wasting, normal or subnormal serum calcium levels with hypocalciuria, normal or low serum levels of 1.25(OH)<sub>2</sub> vitamin D, and normal serum levels of parathyroid hormone, while severity varies.<sup>16</sup> The most common symptom in teeth is the development of spontaneous infectious abscesses, which are not caused by trauma or decay. However, it was linked to Dentinogenesis imperfecta in our case. Treatment for Dentinogenesis imperfecta has several goals: to maintain dental health and preserve the dentition's vitality, form, and size; to provide the patient with an aesthetic appearance at a young age in order to avoid psychological problems; to provide the patient with a functional dentition; to avoid interfering with

the eruption of the remaining permanent teeth and to allow normal facial bone and temporal bone growth. For successful rehabilitation of damaged dentition, a multidisciplinary approach is required.

#### 4. CONCLUSION

Deficiency of any of the nutrients such as Vitamin D, Calcium, or phosphate in childhood results in Rickets which also affects dentition resulting in Dentinogenesis Imperfecta. Dental surgeons must evaluate patients with dentinogenesis imperfecta for associated bone/systemic disorders. General manifestations make an early diagnosis of rickets possible. Physicians must pay attention to the 2 highest-risk groups: pregnant women and young children (i.e. when the crown formation of both primary and permanent teeth occurs). Pediatricians & physicians should diagnose dental manifestations of rickets early to prevent decay progression. They should refer diagnosed patients to a dentist to prevent major dental complications. Dentofacial manifestations of rickets should be diagnosed early to restore the facial,

#### 8. REFERENCES

- Lambert AS, Zhukouskaya V, Rothenbuhler A, Linglart A. X-linked hypophosphatemia: management and treatment prospects. *Joint Bone Spine*. 2019 Nov;86(6):731-8. doi: 10.1016/j.jbspin.2019.01.012, PMID 30711691.
- Gallo de Moraes A, Surani S. Effects of diabetic ketoacidosis in the respiratory system. *World J Diabetes*. 2019 Jan 15;10(1):16-22. doi: 10.4239/wjd.v10.i1.16, PMID 30697367.
- Pitt MJ. Rickets and osteomalacia are still around. *Radiol Clin North Am*. 1991;29(1):97-118. doi: 10.1016/S0033-8389(22)02681-1, PMID 1985332.
- Mayordomo FG, Estrela F, de Aldecoa EA. Dentinogenesis imperfecta: A case report. *Quintessence Int*. 1992;23(12):795-802. PMID 1305296.
- Shields ED, Bixler D, El-Kafrawy AM. A proposed classification for heritable human dentine defects with a description of a new entity. *Arch Oral Biol*. 1973;18(4):543-53. doi: 10.1016/0003-9969(73)90075-7, PMID 4516067.
- Huang B, Sun Y, Maciejewska I, Qin D, Peng T, McIntyre B, et al. Distribution of SIBLING proteins in the organic and inorganic phases of rat dentin and bone. *Eur J Oral Sci*. 2008;116(2):104-12. doi: 10.1111/j.1600-0722.2008.00522.x, PMID 18353003.
- Embery G, Hall R, Waddington R, Septier D, Goldberg M. Proteoglycans in dentinogenesis. *Crit Rev Oral Biol Med*. 2001;12(4):331-49. doi: 10.1177/10454411010120040401, PMID 11603505.
- Sapir S, Shapira J. Dentinogenesis imperfecta: an early treatment strategy. *Pediatr Dent*. 2001;23(3):232-7. PMID 11447953.
- Hart PS, Hart TC. Disorders of human dentin. *Cells Tissues Organs*. 2007;186(1):70-7. doi: 10.1159/000102682, PMID 17627120.
- Holappa H, Nieminen P, Tolva L, Lukinmaa PL, Alaluusua S. Splicing site mutations in dentin sialophosphoprotein causing dentinogenesis imperfecta type II. *Eur J Oral Sci*. 2006;114(5):381-4. doi: 10.1111/j.1600-0722.2006.00391.x, PMID 17026502.
- Albright F, Butler AM, Bloomberg E. Rickets resistant to vitamin D. *Am J Dis Child*. 1937;54:529-47.
- A gene (PEX) with homologies to endopeptidases is mutated in patients with X-linked hypophosphatemic rickets. The HYP consortium. *Nat Genet*. 1995;11(2):130-6. doi: 10.1038/ng1095-130, PMID 7550339.
- Lorenz-Depiereux B, Benet-Pages A, Eckstein G, Tenenbaum-Rakover Y, Wagenstaller J, Tiosano D, et al. Hereditary hypophosphatemic rickets with hypercalciuria is caused by mutations in the sodium-phosphate cotransporter gene SLC34A3. *Am J Hum Genet*. 2006;78(2):193-201. doi: 10.1086/499410, PMID 16358215.
- Brownstein CA, Adler F, Nelson-Williams C, Iijima J, Li P, Imura A, et al. A translocation causing increased alpha-klotho level results in hypophosphatemic rickets and hyperparathyroidism. *Proc Natl Acad Sci U S A*. 2008;105(9):3455-60. doi: 10.1073/pnas.0712361105, PMID 18308935.
- Thompson DL, Sabbagh Y, Tenenhouse HS, Roche PC, Drezner MK, Salisbury JL, et al. Ontogeny of Phex/PHEX protein expression in mouse embryo and subcellular localization in osteoblasts. *J Bone Miner Res*. 2002;17(2):311-20. doi: 10.1359/jbmr.2002.17.2.311, PMID 11811562.
- White KE, Larsson TE, Econs MJ. The roles of specific genes implicated as circulating factors involved in normal and disordered phosphate homeostasis: frizzled related protein-4, matrix extracellular phosphoglycoprotein, and fibroblast growth factor 23. *Endocr Rev*. 2006;27(3):221-41. doi: 10.1210/er.2005-0019, PMID 16467171.

aesthetic and functional dentition and to prevent psychological trauma.

#### 5. ACKNOWLEDGEMENT

We thank the patient for her participative contribution in the study.

#### 6. AUTHORS CONTRIBUTION STATEMENT

Dr. Ramhari Sathawane, Dr. Ashish Lanjekar, Dr. Isha Madne, intellectualized the case and had planned the treatment. Dr. Pranada Deshmukh, Dr. Zareesh Akhtar and Dr. Charwak Tayade has contributed in compiling the literature associated with the case report. Dr. Komal Deotale and Dr. Raksha Jaiswal has provided an important revision of the manuscript

#### 7. CONFLICT OF INTEREST

Conflict of interest declared none.